

Testicular Histoarchitecture in Adrenalectomized Rat Model Treated with Dexamethasone

Dare Joseph Babatunde¹, Folorunso Adekunle Femi², Adekilekun T. Anifat³, Dare Alabi Peter⁴, John Olabode Fatoki⁵, Adekele Opeyemi Samson⁶, Obembe O. Olawale⁷

^{1,2,3,6}Department of Anatomy, Osun State University, Osogbo, Nigeria

⁴Department of Microbiology, Redeemers' University, Ede, Nigeria

⁵Department of Biochemistry, Osun State University Osogbo, Nigeria

⁶Department of Physiology, Osun State University Osogbo, Nigeria

Disclose and conflicts of interest: none to be declared by all authors

ABSTRACT

Introduction: testicular function characterised by two active biological processes; spermatogenesis and steroidogenesis altered by endocrine disruptor and stressors, promoting male infertility. Dexamethasone acts as stressor and hormonal disruptor, while adrenalectomy resultantly depletes stressor hormones. This study investigated the impact of adrenalectomy and dexamethasone on the testicular histological integrity.

Method and Methodology: a total of twenty-five (25) wistar rats were used in this experiment and were randomly divided into five (5) groups of four (4) animals each. Group A (control) received only distilled water, Group B; UNI-ADX (Unilateral adrenalectomy), Group C; BI-ADX (Bilateral adrenalectomy), Group D; UNI-ADX+DEX (Unilateral adrenalectomy + dexamethasone) and Group E; BI-ADX + DEX (Bilateral adrenalectomy + dexamethasone) respectively, the administration was done for the period of one (1) week and animals were sacrificed twenty-24 hours after the last administration.

Result: there was significant reduction in sperm concentration among the animal treated with DEX and reduction in spermatogonia populations associated with abnormal widening of the interstitial spaces in animals exposed to adrenalectomy. This study showed that DEX and Adrenalectomy as stressor on the testicular architecture and caused significant reduction in sperm concentration, spermatogonia populations and abnormal widening of the interstitial spaces in adrenalectomised animals. Testicular nuclei DNA integrity in DEX treated was altered, loss of cell proliferation as well as increase in the expression of tumor protein along the germinal epithelium characterized the testicular architecture in both adrenalectomised and DEX treated animals

Conclusion: this study showed that DEX and Adrenalectomy act as stressors that influences testicular histoarchitecture, disrupt synchronous spermatogenic lineage and consequently alters the sperm characteristics that could be implicated in male infertility

Keywords: Stressor; Infertility; Testes; Adrenalectomy; Dexamethasone; Wistar rats.

Introduction

The testes function majorly in spermatogenesis and steroidogenesis in male gametes and the sexual hormones (androgens) production (Basciani *et al.*, 2010). Spermatogenesis occurs in the seminiferous tubule while steroidogenesis is performed by the leydig/interstitial cells present in the interstitial spaces (Simmons, 2005). The testicular integrity depends on the two compartments for quantitative and qualitative production of spermatocytes. Spermatogenesis and steroidogenesis processes define the testicular functions regulated by the endocrine glands; hypothalamus and pituitary gland (Fariello *et al.*, 2009 and Basciani *et al.* 2010).

In men, 95% of the testosterone is derived from the testes, while the remaining 5% androgen hormones productions are derived from the adrenals ((Simmons, 2005).

Classes of adrenal steroid hormones are required for normal testicular and epididymal functions. Glucocorticoids (GCs) are steroid hormone called corticosteroids responsible for glucose metabolism, and are produced in the adrenal cortex (Biagini and Pich, 2002). Adrenal glands found on the superior pole of the kidneys (suprarenal), have a cortex, the outer portion; and a medulla, the inner portion, hormones of the adrenal cortex are majorly sex-hormone in function and are similar in effect to those produced by the gonads (Cooke *et al.*, 2004). The androgens and the estrogens control the development of sex characteristics. Hormonal production in the adrenal cortex is directly controlled by the anterior pituitary hormone called adrenocorticotrophic hormone (ACTH) (Cooke *et al.*, 2004) and androgens secreted by adrenal cortex includes; Dehydroepiandrosterone, Androstenedione and Testosterone.

Dexamethasone is a synthetic glucocorticoid whose potency to suppress the immune system and it is 20-30 times more potent than that of hydrocortisone. It binds more powerfully to the glucocorticoid receptor than cortisol (Gao *et al.*, 1997). Dexamethasone, an analogue of prednisolone (9 α -fluoro16 α -methylprednisolone), is 25 times more potent and has a longer duration of action than hydrocortisone (cortisol) (Cabrera-Sharp *et al.*, 2013). Corticosteroids such as dexamethasone are anti-inflammatory substances commonly used as therapeutic agents for a variety of clinical conditions including traumatic arthritis and recurrent airway obstruction (Corona *et al.*, 2012 and Dhanabalan *et al.*, 2010). Corticosteroids also have immunosuppressive, lympholytic, and metabolic effects. In addition, they markedly suppress the production of endogenous hydrocortisone (Bremner *et al.*, 1994 and Corona *et al.*, 2012).

Greenwood and Bublrook, 1957, noticed depletion of sex hormones in the ablation performed by adrenalectomy and oophorectomy. Dare *et al.* 2019, revealed defective spermatocytes and altered spermatogonia population in dexamethasone and cryptorchid animals. This study aimed to investigate the impact of adrenalectomy and dexamethasone exposure on the testicular integrity in adult wistar rats

Material and Methods

Experimental Animal

Twenty-Five (25) Adolescent male Wistar rats, weighing 90-105g were obtained and kept at College of Health Sciences Animal House, Osun State University, Osogbo. The animals weighed as they were received and grouped into Five (5) groups in accordance to their body weights, each group was made up of five (5) rats and were kept in separate plastic cages. The animals were comfortably caged in the animal room of the Department of Anatomy, Osogbo and were acclimatized for two weeks under standard laboratory conditions of temperature 27-30°C. Lightening were natural "day-light" such that the animals will be exposed to approximately 12:12 light and dark cycle. The animals were fed with vita feeds with 24hours access to drinking water ad libitum. The animal beddings made up of saw dusts were changed every two days with the cages washed, disinfected with hot water and disinfectant (Dettol). All the experimental procedures were done following the experimental guidelines of Institutional Animal Ethics Committee (IAEC) Oshogbo campus, Osun State.

Animal Grouping

The experimental animals were grouped into Five (5) groups according to the body weights, each group was made up of Five (5) rats and were kept in separate plastic cages. A total number of twenty (25) rats were used in this experiment and were subdivided into five

(5) groups (A, B, C, D and E), each cage containing rats ranging from 95g to 150 g. Group A (control) received only distilled water, Group B; UNI-ADX (Unilateral adrenalectomy), Group C; BI-ADX (Bilateral adrenalectomy), Group D; UNI-ADX+DEX (Unilateral adrenalectomy + dexamethasone) and Group E; BI-ADX + DEX (Bilateral adrenalectomy + dexamethasone) respectively.

Drug Preparation and Administration

Twelve capsules of Dexamethasone (12 mg) were dissolved in 5ml of saline water, done each day for the seven (7) days of administration. Administration of Dexamethasone was done orally using metal oral cannula with a dosage of 0.5ml once a day.

Experimental Procedure

Adrenalectomy

For adrenalectomy, rats were anaesthetized using chloroform and cotton wool and adrenal gland(s) removed through dorsal-lateral incisions utilizing aseptic surgical procedure. The surgical operations were done between the hours of 7:00a.m to 11:00a.m. The operated animals were given special care as special plastic cages were designed for them to check infection, the incision points on the animals were also cleaned twice daily with Methanol and Dettol to checkmate infections. All operated animals were given Saline water and scarified after seven (7) days.

Anaesthetizing rat for adrenalectomy; the anesthetic agent used was Chloroform.

Reasonable size of cotton soaked inside chloroform then held in close contact to the nostrils of the rat for about 45seconds to 1 minute in order to temporarily paralysis the rat and make him unconscious.

Scraping off hair to Aid Easy Incision; after anaesthetizing the rat, the area of the rat to be operated on is wiped with cotton wool soaked in Methanol and then Dettol in other to sterilize the area and aid easy scraping of the rat hair, razor blade is then gently held at an angle 45 and used to scrap off the hair. The adrenal gland is dissected following a midline incision on the abdominal wall. The process is repeated on the opposite side for the bilateral group. The subcutaneous tissue is stitched with a nylon surgical needle because it dissolves after a time period. The skin is stitched with silk surgical needle due to its high durability because of the day-day activity of the rat. Special plastic cage for adrenalectomized rats, the cage was made in such a way that the rats do not have direct contact with the beddings to prevent contamination of the operated area. The cage was innovated by making an elevated net frame.

Animal Sacrifice

Animals were euthanized twenty(24) hours after last administration (to allow complete metabolism of the last administration). The animals were sacrificed

by cervical dislocation. The hair on the abdominal surface was removed and a midline incision was made through the skin and muscles from the xiphisternum to the pubic symphysis, extended laterally to achieve adequate exposure of the abdominal cavity. The testis was harvested following abdominal incision. The testes removed were fixed in Bouin's fluid and processed for histological observation. The spermatozoa were obtained from the caudal part of epididymis for sperm analysis including the sperm count and sperm motility and viability.

Measurement of Sperm Concentration

The testes from each rat were carefully exposed and removed. They were trimmed free of the epididymis and adjoining tissues. The caudal part of the epididymis was removed and placed in a beaker containing 1 mL of physiologic saline solution. Each section was quickly macerated with a pair of sharp scissors and left for a few minutes to release its spermatozoa into the saline solution and placed in a rocker for 10 minutes and allowed to incubate for 2 minutes at room temperature. After incubation, supernatant was diluted at 1:100 using sodium bicarbonate solution and 1 ml formalin (35%). The new improved Neuber's counting chamber (hematocytometer) was used in counting the total number of spermatozoa. About 10 μ l of the diluted sperm suspension was transferred to each counting chamber of the hematocytometer and observed under a light microscope as previously done.

Measurement of sperm motility

The fluid from the caudal epididymis was diluted with Tris buffer solution to 0.5 ml. An aliquot of the solution was then observed under the light microscope. The mean motility estimation was reported as the final score for each sample. The score was done by calculating motile spermatozoa per unit area and was expressed as percentage motility as previously described.

Sperm morphology

The morphology of the spermatozoa was determined using the original dilution for motility, diluted 1:20 with 10% neutral buffered formalin. The sperm cells were categorized based on the presence of one or more abnormal features such as tail defects (short, irregular coiled or multiple tail), neck and middle piece defects (distended, irregular, bent or abnormally thin middle piece), and head defects (small, large, double or detached head). Findings were expressed as percentage of morphologically normal sperm as done in other study.

Histological Preparation

Histological examination was carried out on the tissues fixed in Bouin's fluid. Tissue blocks were sectioned for routine Hematoxylin and Eosin (H/E),

Feulgen DNA, Masson Trichrome, Toluidine blue and Ki-67 migration.

Testes were excised fixed in Bouin's fluid, dehydration was carried out in ascending grades of alcohol, and the dehydrated tissue was cleared in two (2) changes of xylene to allow proper impregnation in paraffin wax. Paraffin wax infiltration was done by completely immersing the tissue in molten wax in the oven at 60°C. Infiltration was done twice for one hour each to remove the clearing agent prior to embedding. The embedding mould was filled with molten paraffin wax and the tissues were inserted in the orientation of the sectioning. The paraffin was then allowed to solidify. Sectioning was done in a rotator microtome at 5 μ m, tissue sections were dewaxed and mounted on a glass slides pass through the descending grades of alcohol for proper hydration and prepared for the staining procedures. The sections were stained using Haematoxylin and Eosin (H/E), Masson Trichrome (MT), Periodic Acid Schiff (PAS), Feulgen and immunohistological staining of Ki-67.

Staining method for Masson Trichrome

Bouin's Solution (It improves the quality of Masson Trichrome Stain): Saturated Picric acid 75 ml, 40% Formaldehyde 25 ml, Glacial acetic acid 5 ml

Weigert's Iron Hematoxylin Solution: Stock Solution A (Hematoxylin 1g, 95% alcohol 100ml), Stock solution B (29% Ferric chloride in water 4ml, Distilled water 95ml, Concentrated Hydrochloric acid 1ml

Equal parts of stock solution A and B are mixed for use.

Biebrich Scarlet-Acid Fuschin Solution: 1% aqueous Biebrich Scarlet 90ml, 1% aqueous Acid fuschin 10 ml, Glacial acetic acid 1 ml.

Phosphomolybdic-Phosphotungstic Acid Solution: 5% Phosphomolybdic acid 25ml, 5% Phosphotungstic acid 25ml.

Aniline Blue Solution: Aniline blue 2.5g, Glacial acetic acid 2ml, Distilled water 100ml

1% Acetic Acid Solution: Glacial acetic acid 1ml, Distilled water 99ml.

Procedures

Testicular tissue samples were deparaffinized and rehydrate using 100% alcohol, 95% alcohol, and 70% alcohol sequentially. The tissues were washed in distilled water, rinsed with running tap water for 5-10 minutes to remove yellow color. Tissue were stained with Weigert's iron hematoxylin solution for 10 minutes, rinsed with running tap water for 10 minutes and washed in distilled water. The tissues were further stained with the Biebrich-Scarlet Acid Fuschin solution for 10-15 minutes, washed in distilled water and differentiated in the phosphomolybdic-phosphotungstic acid solution for 10-15 minutes or until the collagen loses its red color. The stained tissues were transferred to aniline blue solution and stain for 5-10

minutes, rinsed in distilled water and differentiated in 1% acetic acid solution for 2-5 minutes and washed in distilled water. The samples were dehydrated through 95% ethyl alcohol, cleared in xylene and mounted on a glass slide.

Staining method for Feulgen DNA

The Feulgen technique selectively stains DNA, and under controlled conditions. Fixed testicular tissues were treated for 8-10 min with 1N HCl in a water bath at 60°C. Afterwards, the samples were immediately transferred into Schiff's reagent at room temperature (for at least 30 min or until the tissue stains deep purple). Acid hydrolysis removes purine bases from the DNA, thereby unmasking free aldehyde groups. The aldehyde groups then react with Schiff's reagent, which results in the purple staining. RNA is not hydrolyzed by the HCl treatment and, thus, the reaction is DNA-specific.

Schiff's reagent

Schiff's reagent was prepared by pouring 200 mL of boiling distilled water over 1g basic fuchsin. The mixture was thoroughly shaken, cool to 50°C, filtered, and 30 mL 1N HCl was added to the filtrate. The mixture was cooled to room temperature and 1g of potassium metabisulfite (K₂S₂O₅) was added. The solution was allowed to stand overnight in the dark until a light straw or faint pink color develops. 0.5 g charcoal powder was added, shaken, filtered through a coarse filter, and refrigerated in a tightly-stoppered bottle in the dark.

Periodic Acid-Schiff (PAS) Staining

Periodic Acid solution (0.5%): Periodic acid- 0.5g, Distilled water- 100ml

Schiff's Reagent: A good Schiff's reagent turns red-purple in color

The testicular tissues are deparaffinized and hydrate water. Oxidation was carried out by adding 0.5% of the Periodic acid solution for 5 minutes. The oxidized samples were rinsed in distilled water. Aldehydration was done in Schiff reagent for 15 minutes, which turned light pink. The samples were washed in lukewarm tap water, for 5 minutes, until turned dark pink. Counterstaining was achieved using Mayer's Hematoxylin for 1 minute, washed in running tap water for 5 minutes, dehydrated and mounted on synthetic mount medium.

Haematoxylin and Eosin (H&E) staining method

Harri's Hematoxylin stain: A = 1 gm hematoxylin in 10 ml ethanol, B = 20 gm ammonium alum in hot distilled water. Mix A and B, boil and add 0.5 gm of mercuric oxide and filter.

Eosin solution, Yellow eosin = 1 gm, Distilled water = 80 ml, Ethanol = 320 ml, Glacial Acetic Acid = 2 drops. Add 0.5% HCl, and Dilute ammonia water

The samples were deparaffinized, hydrated and drained in xylene. The nuclear staining was done using hematoxylin for 3-5 minutes, washed in running tap water until sections "blue" for 5 minutes or less. Differentiation: selective removal of excess dye from the section was carried out by dipping in 1% acid alcohol (1% HCl in 70% alcohol) for a few seconds. Rinsed in running tap water and dipped in ammonia water until the sections become blue, followed by tap water wash. Counterstain was done in 1% Eosin Y for 10 minutes, washed in tap water for 1-5 minutes and dehydrated in increasing concentration of alcohols, cleared in two xylene baths for cleared Mounted in DPX.

Immunological demonstration of Ki-67 Migration

Testicular tissues deparaffinized in chemical fume hood by 3x changes in xylene, 5min each, and dipped in 2x 100% EtOH, ethanol, 5 min each, 10 min each 90% EtOH, and 70% EtOH, then 50% EtOH and was rinsed in 2x of diH₂O, 2 min each. Antigen retrieval was achieved by boiling for about 30 minutes in citrate buffer. The slide rack containing buffer was placed into a large tip box filled with diH₂O for 2 min. in microwave. The slides were allowed to cool for about 20 min. and were washed 3x in diH₂O for 5 min on shake. The blocking buffer was added to tissue section (5% BSA + 0.3% Triton in PBS) for 1 hr at room temp. The blocking buffer was drained, while primary diluted antibody was added in 1:200 in tube of staining buffer (1% BSA + 0.3% Triton in PBS). Ab solution was diluted to tissue section, incubates at 4oc overnight, and were washed 3x with PBS + .05% Tween for 5 mins on shaker. Secondary Ab was then added, in Diluted antibody 1:400 in tube of staining buffer (1% BSA + 0.3% Triton in PBS), incubated at 1 hr @ room temperature. The solution was washed 5x in PBS + .05% Tween for 5 mins on shaker The slide around tissue were dried, and a drop of DAPI + Prolong Gold Antifade, and gently lay a coverslip on top, avoiding bubbles.

Statistics Analysis

Statistical Package Sciences (SPSS) 16.0 version (Cary, NC, USA) was used for the statistical analyses. All data was expressed as a mean±SEM Differences among the groups were analyzed by one-way ANOVA while Tukey's correction was used to adjust for multiple comparisons. A p value of <0.05 was considered to be statistically significant.

Results

From the Table1 above, Sperm characteristics in control animals showed increased sperm counts compared to the adrenalectomised rats treated with dexamethasone. Significant reduction in the sperm count in adrenalectomised animals relative to the rats administered with dexamethasone. However, in bilateral adrenalectomy treated with dexamethasone showed more reduction in the amount of sperm counts.

Table 1. Sperm analysis in al experimental groups.

Groups	Total Sperm Count (X106/ML)	Sperm Motility (%)		Sperm Morphology (%)	
	Mean±Sem	Motile	Nonmotile	Normal	Abnormal
CONTROL	121.04 ± 1.57	90.00 ± 2.03	10.00± 2.21	89.50 ± 1.24	10.05 ± 1.24
UNI-ADX	59.60 ± 1.72*	71.18 ± 1.81*	28.82± 0.28*	63.45 ± 1.40*	36.55 ± 1.38*
Bi-ADX	50.00 ± 1.09*	61.55 ± 1.22*	38.45± 1.09*	60.07 ± 2.35*	39.93 ± 2.35*
DEX+UNI-ADX	63.60 ± 1.12*	62.50 ± 2.24*	37.50± 1.48*	63.70 ± 1.06*	36.30 ± 1.21*
DEX+Bi-ADX	51.40 ± 0.97*	58.71 ± 0.34*	41.29± 2.10*	54.50 ± 0.79*	45.50 ± 1.02*

Data were presented as mean and standard error of mean (Mean±SEM) *(P<0.05) – statistical significant difference when compared across the group using ANOVA Graph pad prism version 6.

Significant reduction in the sperm motility noticed in dexamethasone treated adrenalectomised animals compared with the Control group. Also insignificant reduction in sperm motility of the Adrenalectomy only group relative to the Dexamethasone treated group was observed. The Bilateral adrenalectomy group rats had more motile sperm as compared with the adrenalectomised rats treated with dexamethasone. However, in contrast bilateral adrenalectomized rats treated with dexamethasone showed significantly higher sperm motility.

For sperm morphology, it was observed that the sperm morphology of the Control group is significantly higher than the Adrenalectomy group. Insignificant changes in the sperm morphology observed in bilateral adrenalectomized animals and dexamethasone treated bilateral adrenalectomised animals.

The normal histo-architecture of rats testes, the seminiferous tubules are lined with the germ cells, spermatids and the ad-luminal areas are packed with the spermatogonia. The spermatogonia lineages were clearly demonstrated, the present of sertoli cells and the leydig cells in the interstitial spaces were demonstrated as well figure 1. There are abnormal widening of the interstitial spaces, it can be seen that there are some cells with irregular shape and an abnormal interstitial space with little interstitial cell of leydig while most cells have their basement membrane in contact with the basement membrane of other cells.Reduce spermatogonia differentiation from the germinal epithelium into a mature spermatocytes and de-arrangement in the spermatogonia along the germinal epithelium observed among the groups D and E adrenalectomised rats treated with Dexamethasone.

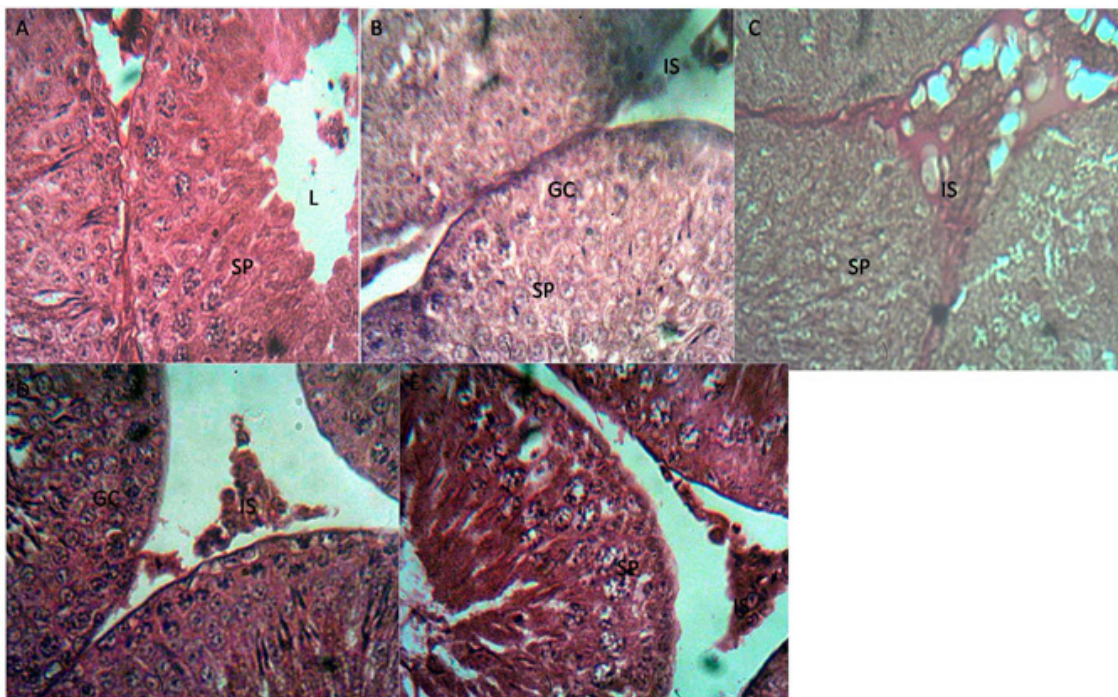


Figure 1. Histological Micrograph of the testes stained with H/E at ×400 in Plate A: Control Animals, SP indicating the spermatogonia cells, IS, the interstitial space and LC, the Leydig cells, testicular histo-architectures preserved. Plate B: Animals in unilateral adrenalectomy (ADX-Uni) well-developed Spermatogonia, Spermatid and Sertoli cells, defined Lumens which are oval and legible interstitial spaces with Interstitial cells of Leydig. Widening of the interstitial spaces noticed. Plate C: Animals in bilateral adrenalectomy (ADX-Bi) well-developed Spermatid and Spermatocyte cells and a wide ad-luminal compartment, Plate D: animals in unilateral adrenalectomy + dexamethasone (ADX+DEX), the Seminiferous tubule, Interstitial space, and the Leydig cell expressed. Abnormal widening of the interstitial spaces associated with reduced leydig cells noticed. Plate E: Animals in bilateral adrenalectomy + dexamethasone (ADX+DEX), well-developed Spermatid and Spermatogonia cells and small lumen, L, interstitial cells of Leydig, I, and Interstitial space, IS.

The bilateral adrenalectomised rats showed increased in sertoli cells within the seminiferous tubules and reduction in the differentiation of the spermatogonia populations, leydig cells reduction was also observed along with the increased adluminal compartment as a result of reduced spermatocytes in the adluminal compartment, however, the interstitial spaces were maintained in close apposition to the basement membrane.

Basement membrane well defined in close apposition with basement membranes of other seminiferous tubules, small lumen, L, interstitial cells of Leydig, I, and Interstitial space characterized the control and the adrenalectomised rats, the connective tissues actively stain in the control animals. Administration of dexamethasone in bilateral adrenalectomised rats is associated with loss of connective tissues along with the de-arrangement in the spermatogonia population across the seminiferous tubules and abnormal widening of the interstitial spaces figure 2.

Fuelgen DNA stains more or less intense depending on the degree of chromatin spiralization and is therefore particularly suitable for highlighting the chromosomes in the nucleus during mitosis. The control and the adrenalectomised rats deeply

expressed chromatin differentiation across the lumen showing the evidences of continuous cell regeneration or cell division compared figure 3. Well defined and clustered with basement membranes of few cells, well-developed Sertoli and Spermatogonia cells and small lumen, L, interstitial cells of Leydig, I, and Interstitial space, IS, However, metachromatically differentiated connective tissues component of mucins and mast cells reduced compared to the plate A, B and C observed in figure 4.

The interstitial space is well defined, the spermatocyte, sertoli and spermatid cells are well developed with the lumen also present, It was observed that the cells have large lumens and closely packed cells causing the presence of small interstitial spaces. There is also presence of large number of spermatocyte and sertoli cells. The cells have irregular shapes with large lumens and are clustered together at one point with the other cells far off with large interstitial space. Figure 5 showed the normal histo-architecture of rats testes as viewed under a microscope using Ki-67 migration. The seminiferous tubules are lined with the germ cells, spermatids and the ad luminal areas are packed with the spermatogonia. The spermatogonia lineages were clearly demonstrated, the present of sertoli cells

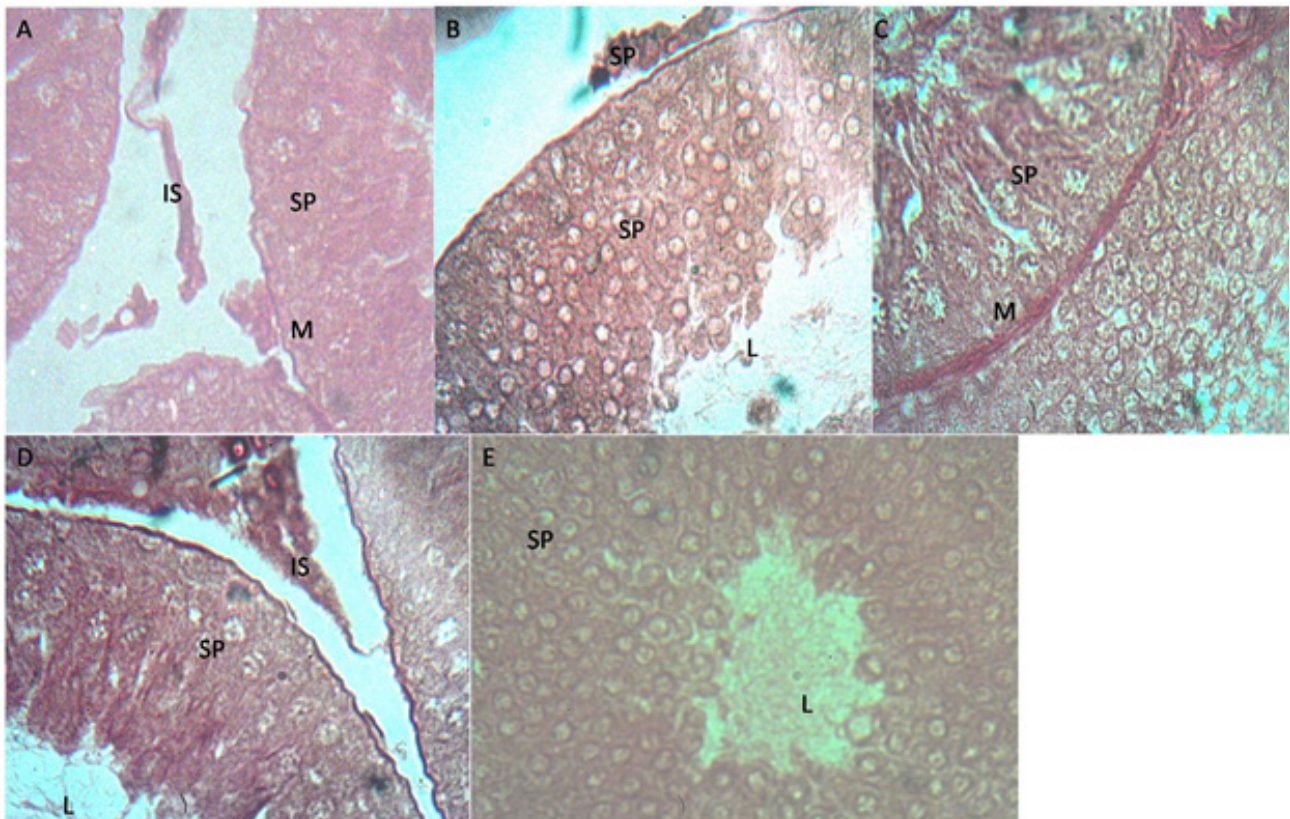


Figure 2. Histological Micrograph of the testes stained with Masson trichromeat x400 in Plate A: The Control animals showing the Basement membrane, Sp spermatogonia, IS, the interstitial space and LC, the Leydig cells, Plate B: Animals in unilateral adrenalectomy (ADX-Uni) showing the Basement membrane which is well defined, well-developed Spermatocytes cells, defined Lumens and legible interstitial spaces. The cells appear oval instead of circular, Plate C: Animals in bilateral rats adrenalectomy (ADX -Bi) , a well-developed and intact basement membrane which is well defined, well-developed Spermatid and Spermatocyte cells and a wide lumen, L, Plate D: Animals in unilateral adrenalectomy + dexamethasone treatment (ADX+DEX), Basement membrane which is well defined and clustered with basement membranes of other cells, small lumen, L, interstitial cells of Leydig, I, and Interstitial space, Plate E: Animals in bilateral rats + dexamethasone (ADX+DEX), Basement membrane, BM, which is well defined and clustered with basement membranes of few cells, well-developed Spermatid and Spermatogonia cells and small lumen, L, interstitial cells of Leydig, I, and Interstitial space, IS.

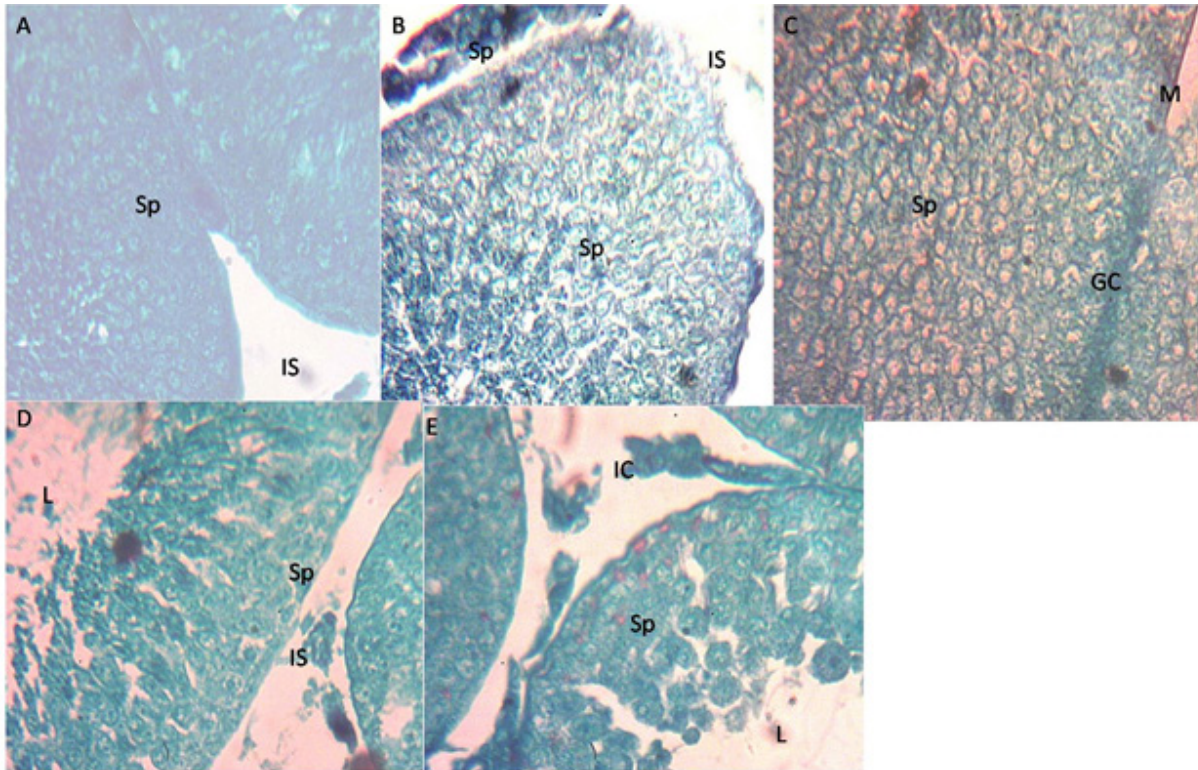


Figure 3. Histological Micrograph of the testes stained with Feulgen DNA at $\times 400$ in Plate A: Control Animals wistar Normal contents of DNA of spermatogenic cells and spermatozoa evidence of mitotic cell division, Plate B: Animals in unilateral adrenalectomy (ADX-Uni), demonstrating the increased contents of DNA of spermatogenic cells and spermatozoa evidence of mitotic cell division as well as in Plate C: animals in bilateral adrenalectomy (ADX-bi). Plate D and E: Animals in unilateral adrenalectomy + dexamethasone (ADX+DEX) and bilateral adrenalectomy + dexamethasone (ADX+DEX), Demonstrated a reduced DNA content in the spermatogenic cells as well as in the spermatozoa present in the adluminal compartment compared with the control animals and the animals adrenalectomised animals without treatment with dexamethasone.

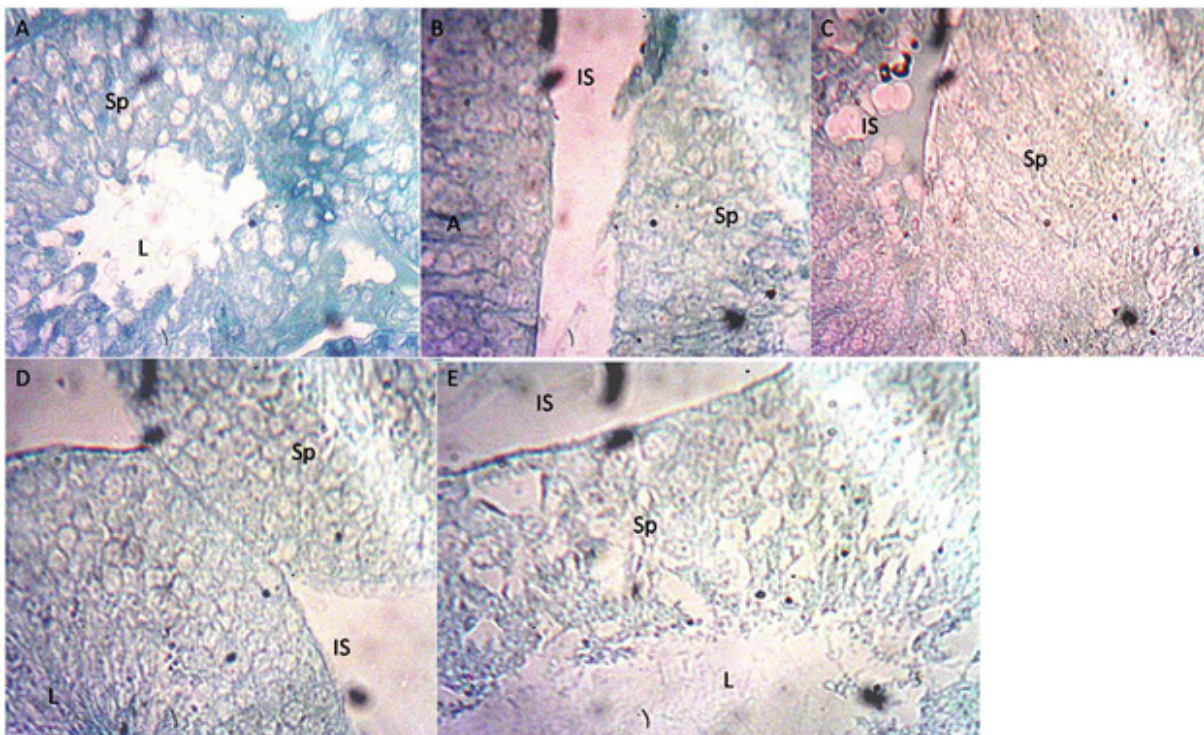


Figure 4. Histological Micrograph of the testes stained with Toluidine blue at $\times 400$ in Plate A Animals in Control wistar indicating the seminiferous tubule, interstitial space and Leydig cells, normal demonstration of the connective tissue component of the mucins (light red), mast cells (purple), Plate B: Animals in unilateral adrenalectomy (ADX-Uni) well defined, well-developed Spermatogonia, Spermatid and Sertoli cells, defined Lumens which are oval and legible interstitial spaces with Interstitial cells of Leydig. Connective tissue component mucins and mast cells metachromatically differentiated in the seminiferous tubule lining. Similar observation in Plate C: Animals in bilateral adrenalectomy (ADX bi) S well defined and clustered with basement membranes of other cells and Interstitial cells of leydig, I, well-developed. Plate D and E: Animals in unilateral adrenalectomy + dexamethasone (ADX+DEX) and bilateral adrenalectomy + dexamethasone (ADX+DEX), well defined and clustered with basement membranes of few cells, well-developed Sertoli and Spermatogonia cells and small lumen, L, interstitial cells of Leydig, I, and Interstitial space, IS, However, metachromatically differentiated connective tissues component of mucins and mast cells reduced compared to the plate A, B and C

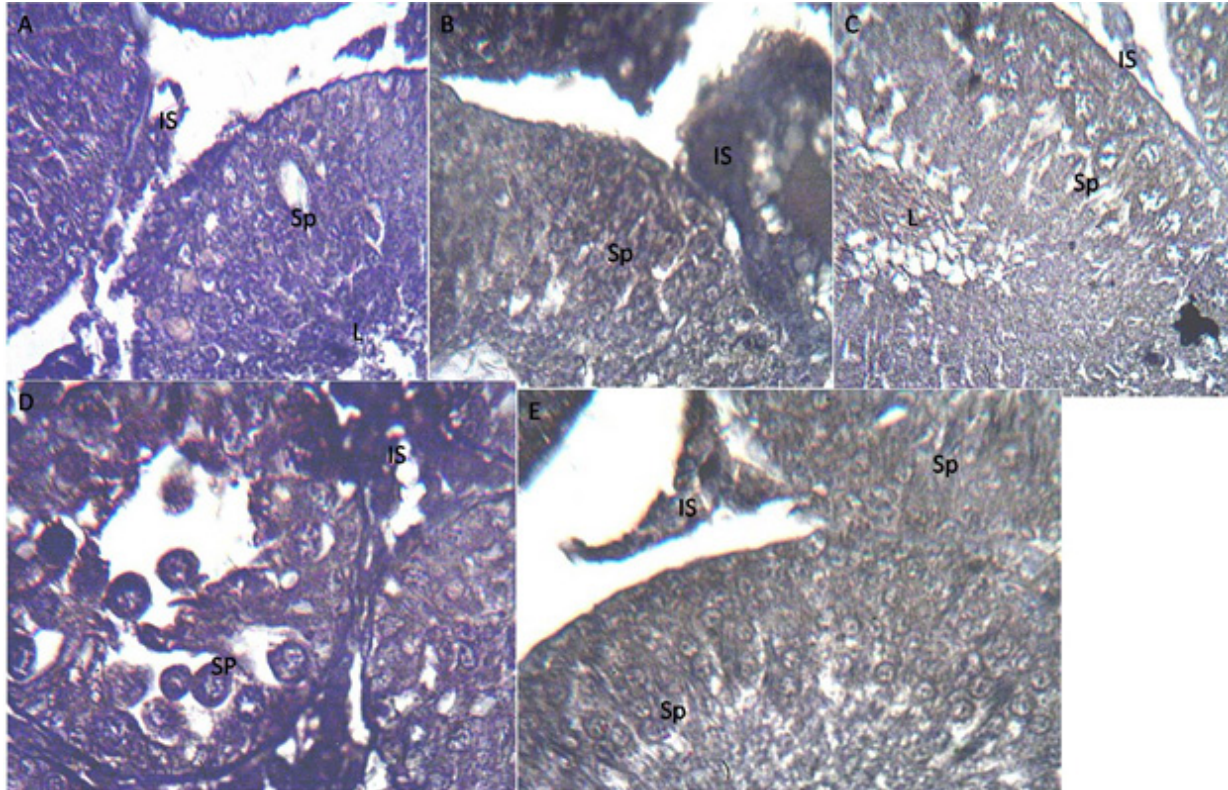


Figure 5. Histological Micrograph of the testes stained with KI-67 migration at $\times 400$ in Plate A: Animals in Control, Basement membrane, ST indicating the seminiferous tubule, IS, the interstitial space and I, the Leydig cells, Plate B: Animals in unilateral adrenalectomy (ADX Uni), Plate C: Animals in Bilateral adrenalectomy (ADX bi) Basement membrane which is well defined and clustered with basement membranes of other cells and Interstitial cells of leydig, well-developed. Ki-67 protein expression relatively demonstrated high in the plate B and C evidence of mitotic activities in the spermatogonia population across the synchronous lineage from the basement membrane to the adluminal compartment. Plate D and E: Animals in unilateral adrenalectomy + dexamethasone (ADX+DEX), Animals in bilateral adrenalectomy + dexamethasone (ADX+DEX), The demonstration of the Ki-67 proteins significantly reduced with pockets of vacuolation across the seminiferous tubule as well as reduced spermatocytes concentration.

and the leydig cells in the interstitial spaces were demonstrated as well. The spermatogonia A and B were shown differentiating. It can be observed that all cells are juxtaposed. The lumens are well defined with most having also an oval shape. There are abnormal widening of the interstitial spaces, it can be seen that there are some cells with irregular shape and an abnormal interstitial space with little interstitial cell of leydig while most cells have their basement membrane in contact with the basement membrane of other cells. Reduce spermatogonia differentiation from the germinal epithelium into a mature spermatocytes and de-arrangement in the spermatogonia along the germinal epithelium was observed.

There were increased in sertoli cells in the seminiferous tubules and reduction in the differentailtion of the spermatogonia populations, leydigs cells reduction was also observed

The interstitial space is well defined; the spermatocyte, sertoli and spermatid cells are well developed with the lumen also present. It is observed that the cells have large lumens and closely packed cells causing the presence of small interstitial spaces. There is also presence of large number of spermatocyte and sertoli cells. The cells are closely packed and the spermatocyte cells are well defined. The basal cells are well formed and the interstitial spaces are small. Some

groups of cells are clustered together and have small interstitial space while a few are far off with relatively large interstitial space. All cells have a well-defined basal membrane and Leydig cells. The spermatid is well developed.

Discussion

In adrenalectomy, cortisol which is a stressor is eliminated and decrease in cortisol will cause increase in testosterone (produced from the Leydig cells); reproductive hormone in the testis consequently enhances spermatogenesis. This study observed in adrenalectomised animals, maintenance of testicular histological integrity; the synchronous differentiation of spermatogonia population from the germ layer across the seminiferous tubules as well as the preservation of the supportive cells of sertoli. These observations in contrast to Silva *et al.*, 2014; where there were disarrangement in spermatogonia and seminiferous tubules in adrenalectomised animals. However, their report equally noted that adrenalectomy slightly reduced sperm motility, and the sperm motility is critical in fertilizing competence of spermatozoa because it is directly correlated with the activity of mitochondria, which provides energy in the form of ATP by oxidative phosphorylation (Yamashiro *et al.*, 2006). Although it has been established that oxidative

phosphorylation is not the only source of energy to support motility, since ATP can be generated by anaerobic glycolysis in the sperm tail (Kerr, 1992), a decrease in the mitochondrial activity may have a negative impact on sperm motility and fertility (Welsh *et al.*, 1982 and Evgeni *et al.*, 2014).

Bilateral adrenalectomy showed more improvement in testicular histology, administration of dexamethasone for adrenalectomized wistar rats caused increase in cortisol hormone in blood and cortisol is regarded as a stressor or stress hormone. It was observed that dexamethasone decreased testicular and epididymal sperm count and increases sertoli cells which causes reduction in leydig cells, this is in line with Silva *et al.*, 2014. A reduction is also noticed in the sperm motility of rats exposed to dexamethasone with a very high reduction in rats that underwent bilateral adrenalectomy and still exposed to dexamethasone. The number of stable sperm relative to the control group also slightly decreased with exposure to dexamethasone. The fact that DEX treatment caused little changes in sperm transit time

(motility) in the caput/corpus epididymis induced by adrenalectomy suggests that glucocorticoids may be involved in the transport of spermatozoa within the proximal regions of the epididymis. The quality of spermatozoa is critical for successful fertilization and subsequent development of the embryo (de Kloet *et al.*, 1998 and Yamashiro *et al.*, 2006). It is possible that the excess of glucocorticoids may disrupt sperm DNA integrity by inducing oxidative stress during spermatogenesis and sperm maturation.

Conclusion

This study has established the impacts of adrenalectomy on testicular architecture and sperm characteristics. The seminiferous tubules lining cells (Germ cell) were seen to be intact, however, spermatogonia population reduced as a result of degeneration, abnormal widening of the interstitial spaces and loss of leydig cells are part of the observations. Dexamethasone and cryptorchidism exert stress and its effects on the histoarchitecture and the sperm characteristics.

References

- Basciani, Cemeli E & Anderson D. (2009) The comet assay in male reproductive toxicology. *Cell BiolToxicol* 25, 81–98
- Simmons, K. (2005). Rat Reproductive System. Retrieved December 17, 2008, from <http://io.uwinnipeg.ca/~simmons/16labman05/lb8pg8.htm>.
- Fariello R, Del Giudice P, Spaine D, Fraietta R, Bertolla R & Cedenho A. (2009) Effect of leukocytospermia and processing by discontinuous density gradient on sperm nuclear DNA fragmentation and mitochondrial activity. *J Assist Reprod Genet* 26, 151–157.
- Biagini G & Pich EM. (2002) Corticosterone administration to rat pups, but not maternal separation, affects sexual maturation and glucocorticoid receptor immunoreactivity in the testis. *PharmacolBiochemBehav* 73, 95–103.
- Cooke PS, Holsberger DR, Witorsch RJ, Sylvester PW, Meredith JM, Treinen KA & Chapin RE. (2004) Thyroid hormone, glucocorticoids, and prolactin at the nexus of physiology, reproduction, and toxicology.
- Cabrera-Sharp V, Mirczuk S, Shervill E, Michael A & Fowkes R. (2013) Regulation of glucocorticoid metabolism in the boar testis and caput epididymidis by the gonadotrophin-cAMP signalling pathway. *Cell Tissue Res* 352, 751–760.
- Gao HB, Ge RS, Lakshmi V, Marandici A & Hardy MP. (1997) Hormonal regulation of oxidative and reductive activities of 11 beta-hydroxysteroid dehydrogenase in rat Leydig cells. *Endocrinology* 138, 156–161.
- Corona G, Jannini EA, Vignozzi L, Rastrelli G & Maggi M. (2012) The hormonal control of ejaculation. *Nat Rev Urol* 9, 508–51.
- Dare BJ, Adekilekun JA, Adenowo TK, Adegoke AA and Folorunso AF (2019) Stress and Testicular Integrity; Impacts of Cryptorchidism and Dexamethasone in Adult Wistar Rats (*Rattus Novergicus*). *J Anat Sci* 10 (2).
- Bulbrook R. D, Greenwood F.C (1957) Persistence of urinary oestrogen excretion after oophorectomy and adrenalectomy, *Br Med. J.* 1957 Mar 23;1(5020):662-6.
- Dhanabalan S, D'Cruz SC & Mathur PP. (2010) Effects of corticosterone and 2,3,7,8-tetrachloro-dibenzo-p-dioxin on epididymal antioxidant system in adult rats. *J BiochemMolToxicol* 24, 242–249.
- Bremner WJ, Millar MR, Sharpe RM & Saunders PT. (1994) Immunohistochemical localization of androgen receptors in the rat testis: evidence for stage-dependent expression and regulation by androgens. *Endocrinology* 135, 1227–1234.
- Balasubramanian K, Aruldas MM & Govindarajulu P. (1987) Effect of corticosterone on rat epididymal lipids. *J Androl* 8, 69–73.
- Au CL, Ngai HK, Yeung CH & Wong PYD. (1978) Effect of adrenalectomy and hormone replacement on sodium and water transport in the perfused rat cauda epididymis. *J Endocrinol* 77, 265–266.
- Baumgartner A, Cemeli E & Anderson D. (2009) The comet assay in male reproductive toxicology. *Cell BiolToxicol* 25, 81–98
- Codrington AM, Hales BF & Robaire B. (2004) Spermiogenic germ cell phase-specific DNA damage following cyclophosphamide exposure. *J Androl* 25, 354–362.
- Quinton R, Duke VM, Robertson A, Kirk JM, Matfin G, de Zoysa PA, Azcona C, MacColl GS, Jacobs HS, 2001 Conway GS *et al.* Idiopathic gonadotrophin deficiency: genetic questions addressed through phenotypic characterization. *ClinEndocrinol (Oxf)* 55:163–174.
- Main KM, Schmidt IM, Skakkebaek NE 2000. A possible role for reproductive hormones in newborn boys: progressive hypogonadism without the postnatal testosterone peak. *J ClinEndocrinolMetab* 85:4905–4907.
- Skakkebaek NE, Rajpert-De Meyts E, Main KM. Testicular dysgenesis syndrome: an increasingly common developmental disorder with environmental aspects. *Hum Reprod.* (2001) 16:972–978.
- Silva EJR, Vendramini V, Restelli, A Bertolla, R.P, Kempinas, W.G Avellar M.C.W (2014) Impact of adrenalectomy and dexamethasone treatment on testicular morphology and sperm parameters in rats: insights into the adrenal control of male reproduction. *Andrology*;2(6):835–46.
- Evgeni E, Charalabopoulos K & Asimakopoulos B. (2014) Human sperm DNA fragmentation and its correlation with conventional semen parameters. *J ReprodInfertil* 15, 2–15.
- Kerr JB. Spontaneous degeneration of germ cells in normal rat testis: assessment of cell types and frequency during the spermatogenic cycle. *J ReprodFertil* 1992; 95:825–830.
- Welsh TH, Jr, Bambino TH & Hsueh AJ. (1982) Mechanism of glucocorticoid-induced suppression of testicular androgen biosynthesis in vitro. *BiolReprod* 27, 1138–1146.

24. Yamashiro H, Kumamoto K, Wang H, Yamashita Y & Terada T. (2006) Effect of semen collection in extender solution on the characteristics of goat spermatozoa. *J ReprodDev*52, 397–406.

25. de Kloet, Francois I, Boehmer AL, Saggese G, Muller J, Hiort O, Sultan C, Clayton P, Brauner R, Cacciari E *et al.* Androgens and fetal growth. *Horm Res* 1998;50:243–244.

Received: May 5, 2022

Accepted: May 12, 2022

Corresponding author

Dare Babatunde Joseph

E-mail: babatunde.dare@uniosun.edu.ng