

# We Need to Talk About the Anterolateral Ligament of the Knee

Ivson Bezerra da Silva<sup>1</sup>, Rafael Lara de Freitas<sup>2</sup>, Jodonai Barbosa da Silva<sup>3</sup>, Eduarda Correia Moretti<sup>4</sup>

<sup>1</sup>Adjunct professor in the Department of Morphology at Federal University of Paraíba, João Pessoa - PB, Brazil

<sup>2</sup>Adjunct professor in the Department of Morphology at Federal University of Paraíba, João Pessoa - PB, Brazil, and Adjunct professor in Orthopedic and Traumatology Department of Medical Sciences School of Paraíba - PB, Brazil

<sup>3</sup>Adjunct professor in the Department of Morphology at Federal University of Paraíba, João Pessoa - PB, Brazil

<sup>4</sup>Adjunct professor in the Human Anatomy Sector of the Institute of Biological and Health Sciences at Federal University of Alagoas, Maceió - AL, Brazil

**Disclose and conflicts of interest: none to be declared by all authors**

## ABSTRACT

**Introduction:** to demonstrate that although anterolateral ligament of the knee (ALL) is not present in the International Anatomical Terminology (IAT), this ligament is a structure with anatomical description and functionality known in several scientific publications.

**Methods:** this is a descriptive study about the importance of standardizing the term “ALL” and describing its anatomy. It comprises three phases: (i) a query to international anatomical terminology, in its most updated version; (ii) the identification of scientific studies that mention the anterolateral ligament in their title and/or abstract; and (iii) the anatomical description of the anterolateral ligament of the knee.

**Results:** regarding the searches in the databases, were found 2562 papers with the term “anterolateral ligament” in 7 different databases (MEDLINE/PubMed, Embase, Scopus, Web of Science, Google Scholar, Cochrane Library, and LILACS). However, this ligament is not present in international anatomical terminology.

**Conclusion:** this paper highlights the features of the ALL and also comprises issues about the gap in the international anatomical terminology.

**Keywords:** Knee; Anatomy; Anterolateral ligament; International anatomical terminology.

## Introduction

It was characterized as ligament only in 2013<sup>1</sup>, but the anterolateral ligament of the knee (ALL) was described by Dr. Paul Segond as a “pearly, fibrous band” attached to his flake fracture<sup>2</sup>, a constant avulsion fracture pattern at the anterolateral proximal tibia as a result of forced internal rotation at the knee, since 1879<sup>1</sup>. The anatomic description by Claes and co-workers (2013)<sup>1</sup> was preceded by Hughston co-workers (1976)<sup>3</sup> that described the ALL as the mid-third lateral capsular ligament, as well as by Johnson (1979)<sup>4</sup>, Haims *et al.* 2003<sup>5</sup> and Moorman & LaPrade, 2005<sup>6</sup>. Further on, Irvine and co-workers (1987)<sup>7</sup> described the ALL as the anterior band of the lateral collateral ligament. In 2001, Campos and co-workers reported the ALL as the anterior oblique band<sup>8</sup>, and in 2007 and 2012 as the anterolateral ligament<sup>9,10</sup>. Recently, Wasdev and co-workers (2023)<sup>11</sup> published that ALL is a crucial part of the anterolateral complex of the knee, providing rotator stability to the knee.

Although, in the literature, different terms are used by describing the ALL for decades, the International Anatomical Terminology (IAT) does not present this structure in its documents yet. Therefore, the goal of the present manuscript is to demonstrate that although

ALL is not present in the IAT, this ligament is a structure with anatomical description and functionality known in several scientific publications.

## Material and Methods

This is a qualitative and descriptive study conducted in October/2023. It explores the need to recognize the existence of a “new” structure belonging to the knee complex: the anterolateral ligament. This need was identified by anatomy professors of Federal University of Paraíba-Brazil and Federal University of Alagoas-Brazil, and by health professionals who evaluate and treat the knee (conservatively and/or surgically).

The proposal of this study comprises three phases: (i) a query to international anatomical terminology, in its most updated version; (ii) the identification of scientific studies that mention the anterolateral ligament in their title and/or abstract; and (iii) the anatomical description of the anterolateral ligament of the knee.

During the first phase of the study, the authors checked all structures related to the knee joint in the IAT, in its most updated version (2019), which is available at the following electronic address: <https://ta2viewer.openanatomy.org><sup>12</sup>. The purpose of consulting the IAT

was to verify whether the anterolateral ligament of the knee was really not officially listed in that terminology.

The second phase involved a search conducted in the main health databases on October 2, 2023. The databases Medical Literature Analysis and Retrieval System Online (MEDLINE) via PubMed, Excerpta Medica Database (Embase), Cochrane Library, Literatura Latino-Americana e do Caribe em Ciências da Saúde (LILACS), Scholar Google, Scopus and Web of Science were consulted, and the search strategy used in each database is shown in Table 1. In this context, it is emphasized that there was no restriction regarding the period and language of publications.

Finally, the third phase was about a detailed anatomical description of the anterolateral ligament of knee, using the latest and most updated scientific

literature. Additionally, images of the anterolateral ligament of the knee were collected from a living individual (undergoing surgery).

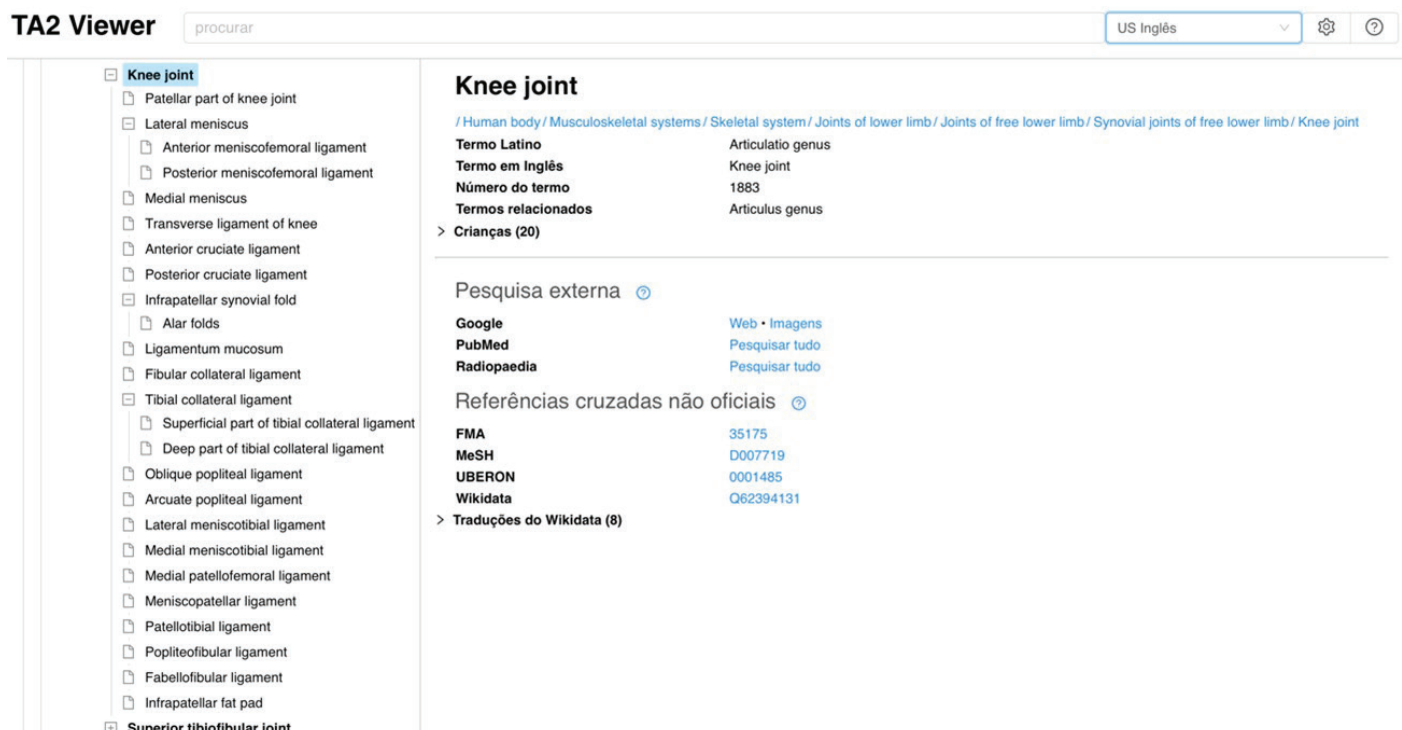
## Results

### Phase I: consultation of international anatomical terminology

The online platform that makes it possible to consult the most updated version of international anatomical terminology is called “TA2Viewer”. This platform is the result of a partnership between the Federative International Program of Anatomical Terminology and The Open Anatomy Project at Brigham and Women’s Hospital in Boston. As shown in Figure 1, querying TA2Viewer shows that the anterolateral ligament of the knee is not officially listed in the IAT. It should be noted

**Table 1.** Search strategies used in each database to identify articles that mentioned the anterolateral ligament of the knee in the title and/or abstract.

Database	Search Strategy
MEDLINE/PubMed	(“Knee”[tiab]) AND (“anterolateral ligament”[tiab])
Embase	knee:ab,ti AND ‘anterolateral ligament’:ab,ti
Cochrane Library	#1 Knee:ti,ab #2 “anterolateral ligament”:ti,ab #3 #1 AND #2
LILACS	(ti:Joelho OR ab:Joelho OR ti:Knee OR ab:Knee OR ti:Rodilla OR ab:Rodilla OR ti:Genou OR ab:Genou) AND (ti:“anterolateral ligament” OR ab:“anterolateral ligament”)
Scholar Google	allintitle: “anterolateral ligament” “knee”
Scopus	TITLE-ABS-KEY ( “Knee” AND “anterolateral ligament” )
Web of Science	(TI=“Knee” OR AB=“Knee”) AND (TI=“anterolateral ligament” OR AB=“anterolateral ligament”)



**Figure 1.** Print screen from TAViewer2 that shows the structures that make up the knee joint and are officially listed in the IAT, 2019 version.

that the following knee ligaments are officially listed in the IAT: anterior meniscomfemoral ligament, posterior meniscomfemoral ligament, transverse ligament of knee, anterior cruciate ligament, posterior cruciate ligament, ligamentum mucosum, fibular collateral ligament, tibial collateral ligament, oblique popliteal ligament, arcuate popliteal ligament, lateral meniscotibial ligament, medial meniscotibial ligament, medial patellofemoral ligament, meniscopatellar ligament, patellotibial ligament, popliteofibular ligament, and fabellofibular ligament.

### Phase II: database searches

Regarding the searches in the databases, the following data can be mentioned: the search carried out in MEDLINE/PubMed resulted in a total of 512 scientific papers found mentioning the anterolateral ligament of the knee in the title and/or in the abstract, while in Embase the number of records found was 567. Searches in Scopus, Web of Science, and Google Scholar also found a high number of records. In Scopus, 659 articles that mentioned the anterolateral ligament of the knee in the title and/or abstract were found, while in Web of Science there were 431. In Google Scholar, 335 records indicated the referred ligament only in the title. Finally, the result of the search in the Cochrane Library showed that 39 papers had the anterolateral ligament of the knee in the title and/or in the abstract, and in LILACS there were 19.

### Phase III: anatomy description

Claes and co-workers (2013)<sup>1</sup> described the ALL as a ligamentous structure identified at the anterolateral side of the knee joint connecting the femur with the tibia, distinct from the lateral collateral ligament (LCL) and the iliotibial band (ITB). The origin of this ligament was located on the prominence of the lateral femoral epicondyle, anterior to the socket from which the LCL originated, and proximal and posterior to the insertion of the popliteus tendon. The tibial insertion of the ALL is situated posterior to Gerdy's tubercle<sup>1</sup>, an elevated semicircular structure, on the proximal tibia, directly inferior to the edge of the tibial plateau<sup>13</sup>.

The ALL (Figure 2) functions are not completely clear. However, according to its morphologic characteristics, it is suggested that this ligament is an important structure to contribute to the stabilization of the knee medial rotation, especially when the knee is between 30° and 90° of flexion. Thus, the ALL appears to be involved in the pivot shift phenomenon<sup>1</sup>.

### Discussion

The results showed that the ALL is not present at International Anatomical Terminology, although this ligament is known in clinical context. The searches in health databases revealed that the ALL had been described since 1879 but it was characterized as ligament only in 2013<sup>1</sup>.

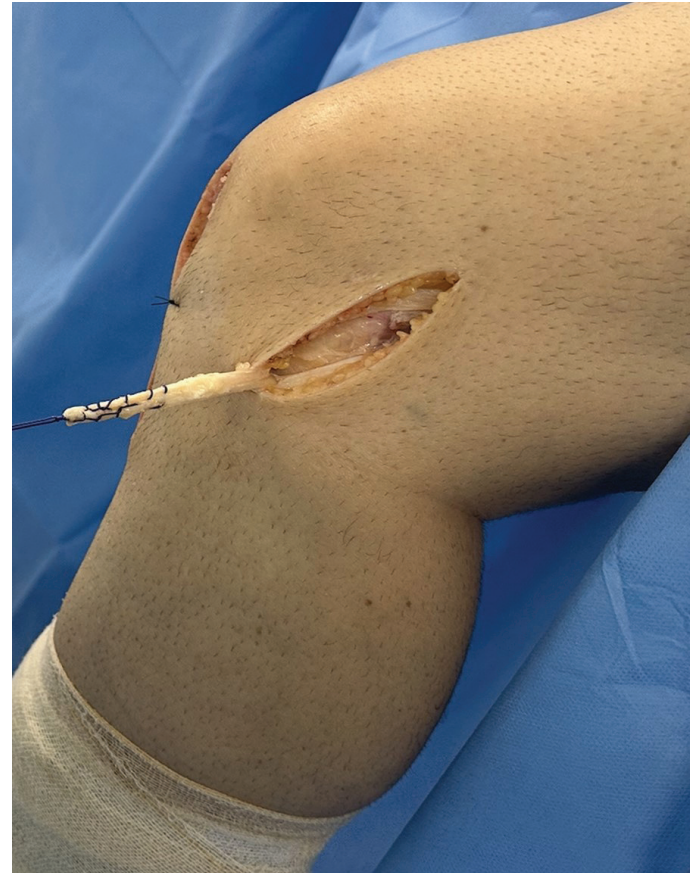

Figure 2. Iliotibial band as ALL graft.

Further investigations noted that the femoral attachment of the ALL is variable<sup>14-20</sup>. In 52 cadavers, Daggett and co-workers (2016) looked specifically at the femoral attachment and confirmed that it varied from anterior and distal to the lateral epicondyle to more proximal and posterior<sup>21</sup>. These finds did not vary with sex, however the thickness of the ligament was nearly double in men<sup>22</sup>.

Some studies, in cadavers, did not identify the ALL consistently and concluded that the ALL may be a thickening of the joint capsule rather than a discrete structure<sup>23-24</sup>, nevertheless there are substantial studies that show the morphology of the ALL, as well as its function<sup>25</sup>.

Although the ALL had been characterized as ligament 10 years ago, the anatomical books and atlases do not show this structure in their drawings yet, probably because the IAT still did not recognize it. If the readers and students have questions about the ALL, they will not be able to find it in the main anatomical books and atlases. When inappropriate nomenclatures are used in the health field, this can bring an educational impairment, for this reason is important to follow the IAT in the process of teaching and learning, and scientific practice.

The absence of the anatomical structure in the IAT can make it difficult for the students to learn and the communications among professors, students, and health professionals. Sometimes different terms for

the same structure are used and this enlarges the anatomical vocabulary. The inconsistency in the use of anatomical terms may result in misunderstandings and mistakes in scientific writing. Furthermore, the use of confusing terminology such as “anterolateral capsule”, “anterolateral complex”, “capsule-osseous layer of the ITB”, etc. should be avoided when explicitly the ALL is investigated to allow data integration into the growing body of knowledge on this interesting structure.

The research on the ALL has increased substantially over the last 10 years, although some debate continues concerning its anatomy, it is absolutely clear that the ALL exists and is distinct from the lateral collateral ligament and the iliotibial band, with anatomical description and functionality known.

It is emphasized that the International Anatomical

Terminology is the reference document for describing the correct terms to be used and that any term not in this document is considered nonexistent and/or wrong.

Given the above, the authors want to stress that this research paper has just one single goal: highlight and insert the appropriate terminology to the ALL. As with every significant scientific progression, the more we learn from studying one subject, the more questions and issues seem to arise. New structures can be described even when we believe that every anatomical element has been pointed out. As long as the most exciting things have been described in anatomical research, one will eventually be able to see the bigger picture in these enigmatic instability patterns of the human knee.

## References

- Claes S, Vereecke E, Maes M, *et al* (2013) Anatomy of the anterolateral ligament of the knee. *J Anat* 223(4):321-8. <https://doi.org/10.1111/joa.12087>.
- Segond P (1879) Recherches cliniques et experimentales sur les epaulements sanguins du genou par entorse. *Progres Medical* (Paris) (accessible from <http://www.patrimoine.edilivre.com/>), 1-85.
- Hughston JC, Andrews JR, Cross MJ, *et al* (1976) Classification of knee ligament instabilities. Part II. The lateral compartment. *J Bone Joint Surg Am* 58, 173-179.
- Johnson LL (1979) Lateral capsular ligament complex: anatomical and surgical considerations. *Am J Sports Med* 7, 156-160.
- Haims AH, Medvecky MJ, Pavlovich R Jr, *et al* (2003) MR imaging of the anatomy of and injuries to the lateral and posterolateral aspects of the knee. *Am J Roentgenol* 180, 647-653. <https://doi.org/10.2214/ajr.180.3.1800647>.
- Moorman CT 3rd, LaPrade RF (2005) Anatomy and biomechanics of the posterolateral corner of the knee. *J Knee Surg* 18,137-145. <https://doi.org/10.1055/s-0030-1248172>.
- Irvine GB, Dias JJ, Finlay DB (1987) Segond fractures of the lateral tibial condyle: brief report. *J Bone Joint Surg Br* 69,613-614.
- Campos JC, Chung CB, Lektrakul N, *et al* (2001) Pathogenesis of the Segond fracture: anatomic and MR imaging evidence of an iliotibial tract or anterior oblique band avulsion. *Radiology*. 219(2):381-6. <https://doi.org/10.1148/radiology.219.2.r01ma23381>.
- Vieira EL, Vieira EA, da Silva RT, *et al* (2007) An anatomic study of the iliotibial tract. *Arthroscopy* 23, 269-274. <https://doi.org/10.1016/j.arthro.2006.11.019>.
- Vincent JP, Magnussen RA, Gezmez F, *et al* (2012) The anterolateral ligament of the human knee: an anatomic and histologic study. *Knee Surg Sports Traumatol Arthrosc* 20(1):147-52. <https://doi.org/10.1007/s00167-011-1580-3>.
- Wasdev A, Anoop PMS, Krishnan R, *et al* (2023) Anatomical Landmark Technique for Femoral Tunnel Placement of Lateral Extra-Articular Tenodesis. *Arthrosc Tech* 24;12(5):e779-e786. doi:<https://doi.org/10.1016/j.eats.2023.02.007>
- TA2 Viewer - Terminologia Anatomica. 2<sup>nd</sup> Edition (2019). <https://ta2viewer.openanatomy.org>. Accessed October 10, 2023.
- Donegan DJ, Seigerman DA, Yoon RS, *et al* (2015) Gerdy's tubercle: the lighthouse to the knee. *J Orthop Trauma* 29(2):e51-3. <https://doi.org/10.1097/BOT.0000000000000196>
- De Carli A, Monaco E, Mazza D, *et al* (2018) Assessment of the anterolateral ligament of the knee by magnetic resonance imaging. *Joints* 2;6(3):153-6. <https://doi.org/10.1016/j.arthro.2016.05.009>
- Dodds AL, Halewood C, Gupte CM, *et al* (2014) The anterolateral ligament: anatomy, length changes and association with the Segond fracture. *Bone Joint J* 96-B(3): 325-31. <https://doi.org/10.1302/0301-620X.96B3.33033>
- Helito CP, Demange MK, Bonadio MB, *et al* (2013) Anatomy and histology of the knee anterolateral ligament. *Orthop J Sports Med* 1(7): 2325967113513546. <https://doi.org/10.1177/2325967113513546>
- Helito CP, Helito PV, Bonadio MB, *et al* (2015) Correlation of magnetic resonance imaging with knee anterolateral ligament anatomy: a cadaveric study. *Orthop J Sports Med* 3(12):2325967115621024. <https://doi.org/10.1177/2325967115621024>
- Kennedy MI, Claes S, Fuso FA, *et al* (2015) The anterolateral ligament: an anatomic, radiographic, and biomechanical analysis. *Am J Sports Med* 43(7): 1606-1615. <https://doi.org/10.1177/0363546515578253>
- Rustagi SM, Gopal P, Ahuja MS, *et al* (2019) The anterolateral ligament of the knee: descriptive anatomy and clinical correlation. *Indian J Orthop* 53(1):89-93. [https://doi.org/10.4103/ortho.IJOrtho\\_137\\_17](https://doi.org/10.4103/ortho.IJOrtho_137_17)
- Klontzas ME, Maris TG, Zibis AH, *et al* (2016) Normal magnetic resonance imaging anatomy of the anterolateral knee ligament with a T2/T1-weighted 3-dimensional sequence: a feasibility study. *Can Assoc Radiol J* 67(1):52-9. <https://doi.org/10.1016/j.carj.2015.08.004>
- Daggett M, Ockuly AC, Cullen M, *et al* (2016) Femoral origin of the anterolateral ligament: an anatomic analysis. *Arthroscopy* 32(5): 835-41. doi:<https://doi.org/10.1016/j.arthro.2015.10.006>
- Daggett M, Helito C, Cullen M, *et al* (2017) The anterolateral ligament: an anatomic study on sex-based differences. *Orthop J Sports Med* 5(2):2325967116689387. doi:<https://doi.org/10.1177/2325967116689387>
- Lazar Stijak, Marko Bumbaširević, Vidosava Radonjić, *et al* (2016) Anatomic description of the anterolateral ligament of the knee. *Knee Surg Sports Traumatol Arthrosc* 24(7):2083-8. <https://doi.org/10.1007/s00167-014-3422-6>
- Cho HJ, Kwak DS (2019) Anatomical consideration of the anterolateral ligament of the knee. *Biomed Res Int* 2019:5740473. <https://doi.org/10.1155/2019/5740473>
- Madhan AS, Patel NM (2020) The Anterolateral Ligament of the Knee. *JBJS Rev* 8(6):e0136. <https://doi.org/10.2106/JBJS.RVW.19.00136>

Received: May 3, 2024  
Accepted: August 16, 2024

Corresponding author  
Ivson Bezerra da Silva  
E-mail: [ivson.silva@academico.ufpb.br](mailto:ivson.silva@academico.ufpb.br)