

α -Tocopherol Mitigates Adverse Effects of Potassium Bromate on Hematological Parameters and Markers of Hepatic Function in Rat Model

Adeniran Oluwadamilare Akinola¹, Dayo Rotimi Omotoso², Adekunle Wahab Oyeyemi³, Ooreoluwa Ololade Daramola⁴, Victor Emojevwe¹

¹D1Department of Physiology, University of Medical Sciences, Ondo-City, Ondo State, Nigeria

²Department of Human Anatomy, Redeemer's University, Ede, Osun State, Nigeria

³Department of Physiology, Osun State University, Osogbo, Osun State, Nigeria

⁴Department of Physiology, Redeemer's University, Ede, Osun State, Nigeria

Disclose and conflicts of interest: none to be declared by all authors

ABSTRACT

Introduction: α -tocopherol is an antioxidant which protects tissues from oxidative stress via inhibition of free radicals production and lipid peroxidation after exposure to tissue toxicants. The potassium bromate is a food additive which causes toxic effects on tissues through generation of reactive oxygen species and impairment of antioxidant system. The current study was aimed to assess the mitigating activity of α -tocopherol on adverse effects of potassium bromate on haematological parameters and hepatic function markers in rats.

Materials and Methods: Twenty Wistar rats were equally grouped into four (1-4) and respectively administered with distilled water, α -tocopherol (50mg/kg), potassium bromate (25mg/kg) and α -tocopherol (50mg/kg) + potassium bromate (25mg/kg) for twenty eight days. Blood sample of study animals was collected and employed for haematological and hepatic function analysis.

Results: The findings of this study showed that exposure to potassium bromate causes adverse effect on haematological parameters (erythrocyte count, haematocrit, haemoglobin, platelet count, neutrophil count, leucocyte count, lymphocyte count and monocyte count) and markers of hepatic function (ALP, ALT and AST) in the study animals. However, co-treatment with α -tocopherol showed significant mitigation on the adverse effect of the potassium bromate exposure.

Conclusion: The potency of α -tocopherol as an antioxidant demonstrated its efficacy in mitigating the adverse effects of potassium bromate on haematological parameters and markers of hepatic tissue function. Hence, α -tocopherol may provide a possible solution to tissue toxicities mediated by exposure to potassium bromate.

Keywords: α -tocopherol; Potassium bromate; Haematological parameters; Liver function.

Introduction

The vitamin E is a lipophilic vitamin which is readily abundant in food substances such as cereals, vegetables oils, eggs, fruits, meats and so on.¹ It is essentially a group of eight lipophilic compounds which include four tocopherols (α -, β -, γ -, and δ) and four tocotrienols (α -, β -, γ -, and δ) that vary based on the methylation of their chromanol heads and saturation of their side chain.² The α -tocopherol and γ -tocopherol are the most abundant forms of vitamin E in the diet. However, α -tocopherol (TP) is the most biologically active form in mammals which functions to reverse vitamin E deficiency.^{3,4} TP is also a lipophilic antioxidant which is readily incorporated into the cell membrane and protects the membrane from oxidative stress after direct or indirect exposure to tissue toxicants via inhibition of free radicals production and lipid peroxidation.⁵⁻⁷

Potassium bromate (PBR) is an oxidizing agent employed in the baking industry because it is one of the cheapest and most effective agent used to improve dough as it affects its gelatinization, viscosity and swelling, helps to remove sulfhydryl group and

form disulfide linkages thereby improving the bread properties.⁸ However, the PBR also causes toxic effects on body tissues through lipid peroxidation and oxidative tissue damage following the generation of reactive oxygen species (ROS) and impairment of tissue antioxidant system.^{9,10} The PBR reportedly induces liver tissue damage through derangement of the supporting cellular and cytoskeletal architecture of the tissue thereby adversely imparting the hepatic tissue function.¹¹ Toxicological studies have proven the PBR to be cytotoxic, carcinogenic and mutagenic with diverse health complications associated with its consumption. The International Agency for Research on Cancer (IARC) has classified PBR as a potential human carcinogen under the class 2B and this has prompted many countries to declare a partial or complete ban on PBR consumption.⁸

Due to the earlier reported usefulness of PBR in the baking industry, its consumption still persists especially in many developing countries. Therefore, food nutrients, additives or supplements that could mitigate the adverse effects of PBR on body tissues are worth finding out. This study was carried out to assess

the potency of α -tocopherol in mitigating adverse effects of potassium bromate on the hematological parameters and hepatic function in experimental Wistar rats.

Materials and Methods

Experimental animals

This study involved twenty adult Wistar rats with body weight between 160 g - 180 g. The animals were housed under standard laboratory conditions in the Animal House of the University of Medical Sciences, Ondo City, Ondo State, Nigeria. They were fed with pelletized mash and given drinking water. The experimental animal handling was in accordance with the guidelines by the National Institutes of Health.¹² This study was approved by Research and Ethics Committee of the University of Medical Sciences, Ondo City, Nigeria (PHS/16/0460).

Experimental design

The study animals were randomly divided into four groups (1-4) comprising five animals per group ($n=5$) and received the treatment regimen for twenty eight (28) days. Group 1 (control) animals were treated with distilled water daily and orally; group 2 animals received only TP (50 mg/kg) daily and orally; group 3 animals received only PBR (25 mg/kg) daily and intraperitoneally (i.p.) while the group 4 animals were treated with TP (as in group 2) + PBR (as in group 3). The treatment dosages were considered safe for the experimental study.^{13,14} After the treatment period, the study animals were anesthetized with an i.p. injection of sodium thiopental (50 mg/kg), the blood plasma was collected from study animals via cardiac puncture into Ethylenediaminetetraacetic acid (EDTA) and plain bottles for subsequent hematological and biochemical analysis respectively.

Hematological analysis

The blood samples collected in EDTA bottles were analyzed with haematology analyzer (Mindray

Auto Hematology Analyzer, BC-200,USA) following the manufacturer's guidelines. The haematological parameters analyzed include erythrocyte count, haematocrit, haemoglobin concentration, platelet count, neutrophil count, total leucocyte count, lymphocyte count, and monocyte count following the method described by Yakubu *et al.*¹⁵

Hepatic function analysis

The blood collected in plain tubes was centrifuged at 4,000 revolution per minute (rpm) for 10 minutes to obtain clear serum. The serum was analyzed using Randox kits (Randox Clinical Diagnostic Solutions, UK) and hepatic function marker enzymes including alkaline phosphatase (ALP), alanine aminotransferase (ALT) and aspartate aminotransferase (AST) were assayed following the method described by Enenebeaku *et al.*¹⁶

Statistical Analysis

The results were expressed as mean \pm standard error of mean in graphs. The significant differences between mean values were determined by one-way analysis of variance (ANOVA) followed by Tukey's Honestly Significant Difference (HSD). The confidence interval level was 95% and $p < 0.05$ was considered statistically significant.

Results

Effect of TP on haematological parameters in rats treated with PBR

According to the findings of this study, the treatment with PBR caused adverse effect on the haematological parameters in the study animals (Figure 1-4). Specifically, the PBR treatment resulted into significant ($p < 0.05$) reduction in the erythrocyte count, haematocrit, haemoglobin count, platelet count, neutrophil count and total leucocyte count in the serum of the experimental animals. Conversely, the co-administration of TP helps to mitigate the adverse effect of PBR exposure on haematological parameters and relatively normalizes the serum levels of the aforementioned haematological parameters.

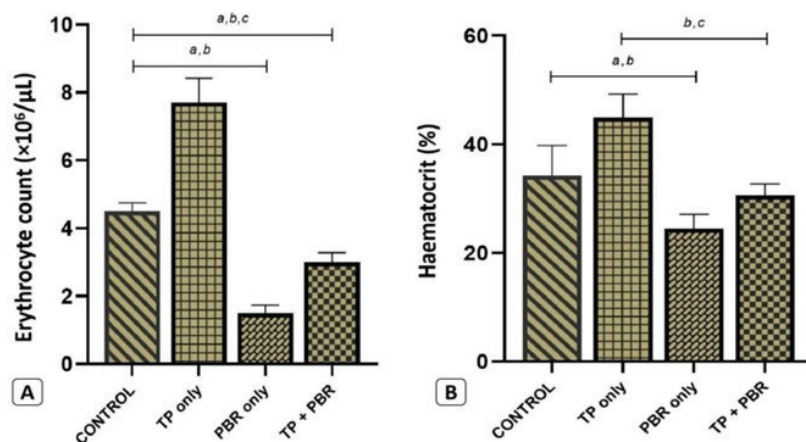


Figure 1. Effect of TP on erythrocyte count (a) and haematocrit (b) in rats treated with PBR. [a, b, indicates significant difference (at $p < 0.05$) compared to group 1 (control) & group 2 (TP only) respectively; c: indicates significant difference (at $p < 0.05$) between group 3 (PBR only) and group 4 (TP+PBR)].

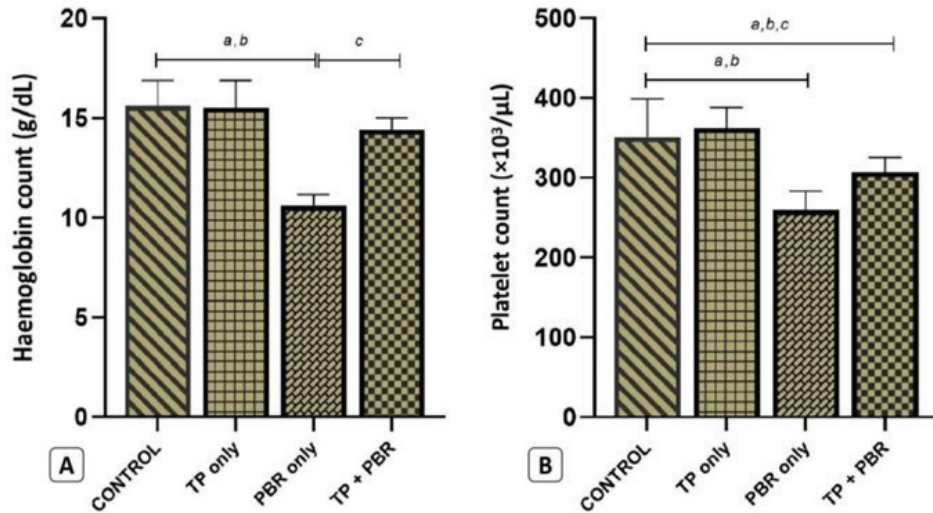


Figure 2. Effect of TP on haemoglobin count (a) and platelet count (b) in rats treated with PBR. [a, b; indicates significant difference (at $p < 0.05$) compared to group 1 (control) & group 2 (TP only) respectively; c: indicates significant difference (at $p < 0.05$) between group 3 (PBR only) and group 4 (TP+PBR)].

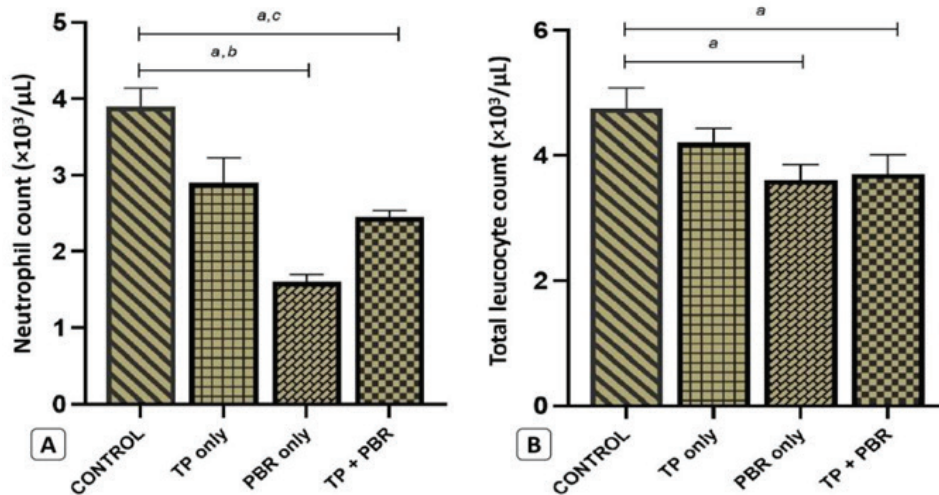


Figure 3. Effect of TP on neutrophil count (a) and total leucocyte count (b) in rats treated with PBR. [a, b; indicates significant difference (at $p < 0.05$) compared to group 1 (control) & group 2 (TP only) respectively; c: indicates significant difference (at $p < 0.05$) between group 3 (PBR only) and group 4 (TP+PBR)].

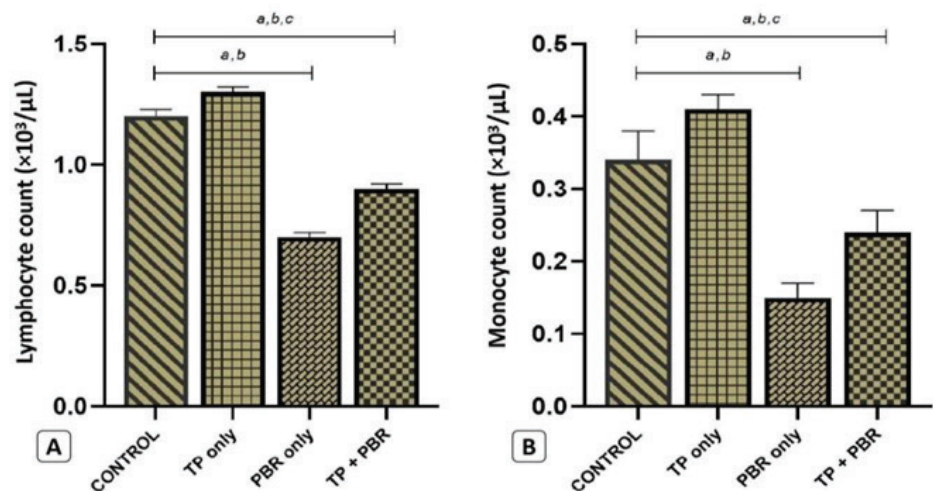


Figure 4. Effect of TP on lymphocyte count (a) and monocyte count (b) in rats treated with PBR. [a, b; indicates significant difference (at $p < 0.05$) compared to group 1 (control) & group 2 (TP only) respectively; c: indicates significant difference (at $p < 0.05$) between group 3 (PBR only) and group 4 (TP+PBR)].

Effect of TP on markers of hepatic function in rats treated with PBR

According to the findings of this study, the treatment with PBR caused significant elevation in the serum concentrations of the hepatic function markers including alkaline phosphatase (ALP), alanine aminotransferase (ALT) and aspartate aminotransferase (AST) (Figure 5). Conversely, the co-administration of TP helps to mitigate the adverse effect of PBR exposure on hepatic function markers and significantly reduced the serum level to relatively normal level.

production of haemoglobin.¹⁹ Moreover, a significant reduction in haemoglobin count and haematocrit in PBR-exposed animals could be due to the production of methaemoglobin which is another form of haemoglobin that has a significantly reduced capacity to bind with oxygen.^{19,20} In addition, the diminution in leucocyte and platelet counts could be linked to the DNA damage caused by PBR-induced oxidative stress.²⁰ This implies that the reduction of haematological parameters, following exposure to tissue toxicant (PBR) in this study, is mainly due to the impairment of the physiological activity of the haematopoietic system.

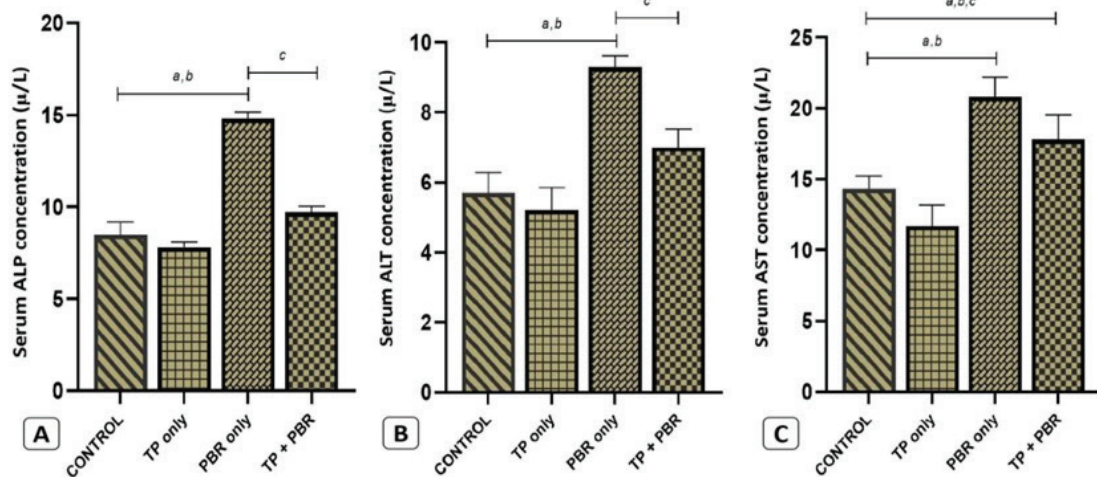


Figure 5. Effect of TP on serum concentrations of ALP (a), ALT (b) and AST (c) in rats treated with PBR. [a, b: indicates significant difference (at $p < 0.05$) compared to group 1 (control) & group 2 (TP only) respectively; c: indicates significant difference (at $p < 0.05$) between group 3 (PBR only) and group 4 (TP+PBR)].

Discussion

Haematological parameters have been assessed to evaluate the toxic effect of exposure to chemical toxicants or environmental pollutants and ameliorative effect of orthodox or herbal medicines against such toxicity.¹⁵⁻¹⁷ In this study, the haematological parameters were assessed to evaluate the toxic effect of PBR exposure and mitigating effect of TP treatment. Based on the findings of this study, it can be observed that all haematological parameters assayed including erythrocytes count, haematocrit, haemoglobin count, platelet count, total leucocytes, neutrophil, lymphocytes and monocytes were adversely affected by the PBR exposure. This was indicated by significant reduction in the haematological parameters among PBR only treated animals (Figures 1-4). The findings of this study show similarity to the findings of Oladele *et al.*, which reported that exposure to PBR resulted into significant decrease in all the haematological indices assessed.¹⁸ However, the results of the study by Achukwu *et al.*, indicated that PBR exposure caused only thrombocytopenia in the study animals.¹³

It has been reported that PBR interferes with the absorption of some dietary nutrients especially iron, hence, its continuous exposure could cause iron-deficient anaemia characterized by decreased

Conversely, the treatment with TP significantly mitigates the adverse effects of PBR on the haematological parameters in the co-treated animals (Figure 1-4). This finding is similar to the results of previous studies which indicated that TP is potent in mitigating adverse effects of chemical toxicants on haematological parameters in experimental models.²¹⁻²³ Essentially, the mitigating effect of TP can be attributed to its antioxidant properties.

Furthermore, the results of this study showed that the exposure to PBR exerted adverse effects on markers of hepatic function which include the ALP, ALT and AST in the PBR only treated animals (Figure 5). These findings are in tandem with the results of the study by Bayomy *et al.*, which reported that PBR exposure resulted into significant increase in the serum levels of AST and ALT.²⁴ The significant increase in the serum levels of these markers are essentially indicative of hepatic tissue damage due to the exposure to PBR.

The PBR has been described as a toxic halogen and environmental toxicant which can be found in contaminated drinking water.²⁵ Induction of oxidative stress, disruption of inflammatory cytokines and deoxyribonucleic acid (DNA) damage have been described as the mechanisms of PBR toxicity *in vivo*.²⁵⁻²⁷ In addition, the PBR mediates the depletion

of enzymatic and non-enzymatic antioxidants and induces lipid peroxidation within the hepatic tissues leading to tissue damage and necrosis.²⁵

Conversely, the treatment with TP significantly mitigates the adverse effects of PBR on the markers of hepatic function in co-treated animals (Figure 5). The results of this study is similar to the findings of previous studies where TP had been reported to effectively mitigate the damaging effect of hepatotoxic agents.²⁸⁻³⁰ Based on their findings, the potency of TP to mitigate the toxic effect of hepatotoxins have been closely linked to its antioxidant properties.

In this study, the mitigating potential of TP on PBR-induced hepatotoxicity is essentially due to its potent antioxidant effect.

Conclusion

The potency of α -tocopherol as an antioxidant demonstrated its efficacy in mitigating the adverse effects of potassium bromate on haematological parameters and markers of hepatic tissue function. Hence, α -tocopherol may provide a possible solution to tissue toxicities mediated by exposure to potassium bromate.

References

1. Traber MG, Bruno RS. Vitamin E. Present Knowledge in Nutrition 11th Edition, 2020; 1:115-36.
2. Astley SB. Antioxidants-Role of antioxidants nutrients in defense systems. Encyclopedia of Food Sciences and Nutrition. 2nd Edition. 2003; 282-289. doi: 10.1016/B0-12-227055-X/00056-0
3. Bruno RS, Mah E. Vitamin E. Reference Module in Biomedical Sciences. 2014; doi:10.1016/B978-0-12-801238-3.00231-2
4. Atkinson J, Manor D, Parker R. Vitamin E. Encyclopedia of Biological Chemistry. 2nd Edition 2013; 545-50. doi: 10.1016/B978-0-12-378630-2.00223-1
5. Omotoso, DR, Ehiemere, WP. Comparative histomorphological assessment of Vitamin E and green tea (*Camellia sinensis*) extract-mediated amelioration of Lead-induced hepatopathy in experimental Wistar rats. *Am J Physiol Biochem Pharmacol* 2020; 10 (1), 1-7.
6. Engelking LR. Vitamin E. Textbook of Veterinary Physiological Chemistry. 3rd Edition. 2015; 294-98.
7. Traber, MG, Stevens, JF. Free radical biology and medicine – Vitamins C and E: Beneficial effects from a mechanistic perspective. *Free Rad Biol Med* 2011;51(5):1000-13.
8. Shanmugavel V, Santhi KK, Kurup AH, Kalakandan S, Anandharaj A, Rawson A. Potassium bromate: Effects on bread components, health, environment and method of analysis: A review. *Food Biochem* 2020; 311:125964. DOI: 10.1016/j.foodchem.2019.125964
9. Khan, MR, Haroon, J, Khan, RA, Bokhari, J, Shabbir, M, Rashid, U. Prevention of KBrO₃- induced cardiotoxicity by *Sonchus asper* in rat. *J Med Plant Res* 2011;(12):2514-20.
10. EL-Deeb, MEE, Abd-EL-Hafez, AAA. Can vitamin C affect the KBrO₃ induced oxidative stress on left ventricular myocardium of adult male albino rats? A histological and immunohistochemical study. *J Microsc Ultrastr* 2015;3:120-136.
11. Awoniran PO, Adeyemi DO. Ethanol extract of *Curcuma longa* rhizome mitigates potassium bromate-induced liver changes in the Wistar rat: Histological, histochemical and immunohistochemical assessments. *Morphol* 2018;102(339):276-88
12. National Institutes of Health. Institutional Administrator's Manual for Laboratory Animal Care and Use. Bethesda: NIH Publication 1988; PMID: 21595115
13. Achukwu PU, Ufelle SA, Ukaejiofo EO, Ejezie FE, Nwachukwu DN, Nwagha UI, Nworie WC, Anyaehie USB. The effect of potassium bromate on some haematological parameters of Wistar rats. *Nig J Physiol Sci* 2009;24(1): 59-61.
14. Miguel FM, Schemitt EG, Colares JR, Hartmann RM, Morgan-Martins MI, Marroni NP. Action of vitamin E on experimental severe acute liver failure. *Arq Gastroenterol* 2017;54(2):123-29.
15. Yakubu MT, Akanji MA, Oladiji AT. Haematological evaluation in male albino rats following chronic administration of aqueous extract of *Fadogia agrestis* stem. *Pharmacog Mag* 2017;3: 34.
16. Enenebeaku UE, Okotcha EN, Oguoma LMO, Mgbemena IC, Enenebeaku CK, Onyeka CA. Biochemical and haematological enhancement activities of aqueous and methanol leaves, stem and roots extracts of *Chasmanthera dependens* (Hochst) and *Dictyandra arborescens* (Welw.) Bulletin Nat Res Centre 2021;45:186
17. Fathy AH, Bashandy MA, Bashandy SAE, Mansour AM, Azab KS. The beneficial effect of natural antioxidants from olive oil with fig and date palm fruit extracts on biochemical and hematological parameters in rats treated with doxorubicin and γ -radiation. *Facets* 2018;3:1 doi: 10.1139/facets-2017-0080
18. Oladele JO, Oyeleke OM, Awosanya OO, Oladele OT. Effect of *Curcuma longa* (Turmeric) against potassium bromate- induced cardiac oxidative damage, haematological and lipid profile alterations in rats. *Singap J Sci Res* 2020;10:8-15. doi: 10.3923/sjsres.2020.8.15
19. Parsons, JL, Chipman, JK. The role of glutathione in DNA damage by potassium bromate in vitro. *Mutagen* 2000;15(4):311-316.
20. Starek A, Starek-Swiechowicz B. Toxicological properties of potassium bromate. *J Pharmacol Reports* 2016;1(3):1000122.
21. Nnamdi OB, Nyebuchi J, Collins AO, Udu ZL. Effects of vitamin E on chronic haematotoxicity of Paraquat exposed male albino rats (*Rattus norvegicus*). *Arch Curr Res Int* 2022;22(3):41-47.
22. Azeez OI, Braimah SF. Mitigating effect of vitamin E on copper sulphate-induced toxicity in African catfish (*Clarias gariepinus*). *Eur J Med Health Sci* 2020;2:4. doi: 10.24018/ejmed.2020.2.4.411
23. Asuquo EN, Mgbeje BIA, Edet EE, Eteng MU. Ameliorating effect of some antioxidants on haematological indices in Chlorpyrifos toxicity induced albino Wistar rats. *Merit Res J Med Med Sci* 2020;8(11):673-78.
24. Bayomy NA, Soliman GM, Abdelaziz EZ. Effect of potassium bromate on the liver of adult male albino rat and a possible protective role of vitamin C: Histological, Immunohistochemical and Biochemical study. *Anat Records* 2016;299(9):1256-69. doi:10.1002/ar.23386
25. Saad HB, Driss D, Amara IB, Boudawara O, Boudawara T, Chaabouni SE, Zeghal KM, Hakim A. Altered hepatic mRNA expression of immune response-associated DNA damage in mice liver induced by potassium bromate: Protective role of vanillin. *Environ Toxicol* 2016;31(12):1796-1807 doi:10.1002/tox.22181
26. Saad HB, Kharrat N, Driss D, Gargouri M, Marrakchi R, Jammoussi, Magne C, Boudawara T, Chaabouni SE, Zeghal KM, Hakim A, Amara IB. Effects of vanillin on potassium bromate-induced neurotoxicity in adult mice: impact on behaviour, oxidative stress, gene expression, inflammation and fatty acid composition. *Arch Physiol Biochem* 2017;123(3):165-174 doi:10.1080/13813455.2017.1283527
27. Saad HB, Driss D, Jaballi I, Ghazzi H, Boudawara O, Droguet M, Magne C, Nasri M, Zeghal KM, Hakim A, Amara IB. Potassium bromate-induced changes in the adult mouse cerebellum are ameliorated by Vanillin. *Biomed Environ Sci* 2018;31(2):115-125 doi:10.3967/bes2018.014

28. Abd Ellatif M, El Karib AO, Dallak M, Eid RA, Al-Ani R, Haidara MA. Vitamin E protects against hepatocyte ultrastructural damage induced by high fat diet in a rat model of pre-diabetes. *Int J Morphol* 2018;36(4):1350-1355.

29. Alahmadi BA, El-Alfy SH, Hemaïd AM, Abdel-Nabi IM. The protective effects of vitamin E against selenium-induced

oxidative damage and hepatotoxicity in rats. *J Taibah Uni Sci* 2020;14(1):709-20. doi:10.1080/16583655.2020.1769256

30. Shotop YM, Al-Suwiti IN. The possible role of vitamins E and C in reducing the toxicity of copper nanoparticles in the kidney and the liver of the rats (*Rattus norvegicus*). *J King Saud Uni - Sci* 2021;33(2):101357. doi:10.1016/j.jksus.2021.101357

Received: December 20, 2022
Accepted: January 10, 2023

Corresponding author
Dayo Rotimi Omotoso
E-mail: dayohmts@gmail.com