Journal of Morphological Sciences
J Morphol Sci
Brazilian Society of Anatomy

Case Report
J Morphol Sci 2020;37:105-109

Bovine Aortic Arch Variation in a Symptomatic Patient

Lincoln da Silva Freitas,[1] Frederico Sassoli Fazan,[2] Fernando José Dias,[3] Valéria Paula Sassoli Fazan[4]

[1]Department of Neuroscience and Behavioral Science, School of Medicine of Ribeirão Preto, University of São Paulo (USP), Ribeirão Preto, SP, Brazil
[2]Department of Physiology, Paulista School of Medicine, Federal University of São Paulo (UNIFESP). São Paulo, SP, Brazil
[3]Department of Integral Dentistry, CICO - Research Center in Dental Sciences, Dental School, Universidad de La Frontera (UFRo), Temuco, Chile
[4]Department of Surgery and Anatomy, School of Medicine of Ribeirão Preto, University of São Paulo (USP), Ribeirão Preto, SP, Brazil

Disclose and conflicts of interest: none to be declared by all authors

ABSTRACT

Introduction: the aortic arch in humans usually gives rise to three great vessels: the first is the brachiocephalic trunk, the second is the left common carotid artery and the third is the left subclavian artery. The brachiocephalic trunk further gives rise to the right subclavian artery and the right common carotid artery. One of the most common variations of the aortic arch branching pattern is the so-called "bovine aortic arch" when the left common carotid artery originates from the brachiocephalic trunk. We report a case of a bovine aortic arch variation identified by magnetic resonance angiography imaging in a patient with clinical neurological symptoms.

Case report: a male 66years old patient with a history of amnesia, dizziness, and headache was being investigated by the neurologists with a suspect of amyloid angiopathy. The magnetic resonance imaging exam showed global cerebral volume loss, lacunar infarcts at the internal capsule and basal nuclei regions on the left and semioval center on the right. The investigation of the blood vessels of the neck by magnetic resonance angiography evidenced an anatomical variation of the aortic arch, the so-called bovine aortic arch, that might be related to the embolic cerebral infarcts in this patient.

Conclusion: Embryological deviations of normal associated with this anatomical variation are discussed. Despite having little or no physiological consequence in the vast majority of patients, aortic arch variations have significant implications for planning interventional vascular radiology and surgical procedures not only in the head and neck but also in the upper limbs.

Keywords: Anatomy, Aortic Arch, Variation, Magnetic Resonance Imaging, Bovine aortic arch.

Introduction

The aortic arch in humans usually gives rise to three great vessels. As described in most anatomy textbooks, in about 70% of the aortic arches in humans,[1] the first branch is the brachiocephalic trunk (innominate artery), the second branch is the left common carotid artery and the third branch is the left subclavian artery.[1-3] The brachiocephalic trunk, the first branch of the aortic arch from right to the left, further gives rise to the right subclavian artery and the right common carotid artery.

One of the most common variations of the aortic arch branching pattern is the so-called "bovine aortic arch",[2-4] when the left common carotid artery does not originate directly from the aortic arch but from the brachiocephalic trunk. This variation is described in frequencies between 9-10%[4-5] to up to 35%[6] of the general population. When sex and ethnicity are taken into consideration, the bovine aortic arch is more frequent in black[1-3,6] compared to Caucasians and also more frequent in women[6].

The two most common subtypes of the bovine aortic arch are described, but the frequency of their appearance is still controversial. In the most common situation,[1-3,6] the aortic arch presents a common trunk giving rise to both, the brachiocephalic trunk and the left common carotid artery. This variation is described to be present in percentages between 13-20%[1-3] from the bovine aortic arch subtype. In the second situation, the left common carotid artery is a branch of the brachiocephalic trunk, arising further cranial from the aortic arch. This situation is reported to be present in frequencies between 7-13%.[1-3] There are several other anatomic variations described for the aortic arch branching pattern in humans but their frequency is very low, usually bellow 1%.[1]

An anatomic variation is usually considered as a statistic definition when there is a deviation in the topography and morphology of structures of the body from those described in the anatomy textbooks and taught in dissecting rooms and clinical practice[7,8]. Usually, to be considered an anatomic variation, this deviation from the most common presentation of a determined structure should not interfere with its function. Thus, anatomic variations are totally benign, being errors of embryologic developmental timing or persistence of normally obliterated structures.[7]

Because understanding the great vessels of the aortic arch and their variations is important not only for anatomists and anatomy teachers but also for both the endovascular interventionist and the diagnostic radiologist, we describe a clinical case of a bovine

DOI: https://doi.org/ 10.51929/jms.37.20.2020
ISSN 2177-0298

aortic arch associated with clinical symptoms and the radiologic investigation.

Case Report

A male 66years old patient with a history of amnesia, dizziness, and headache was being investigated by the neurologists with a suspect of amyloid angiopathy. He was referred to the radiology clinic to be submitted to a magnetic resonance imaging exam (MRI). This first exam was performed with a Siemens Magnetom Espree 1.5-T equipment (Erlangen, Germany). Images were obtained with a slice thickness of 1.15 mm and a gap of 1.0 mm between them. Axial images were obtained on a 256 x 256 matrix with a 20 cm field of view. T1-weighted pulse sequences consisted of 600/25/2(TRITE/excitations), mixed T1-/T2-weighted sequences of 2000/25-35/2, and T2-weighted sequences of 2000/60-70/2.

The images obtained evidenced global cerebral volume loss, lacunar infarcts at the internal capsule and basal nuclei regions on the left and semioval center on the right, as well as several punctiform low signal images in ponderal sequences from susceptibility-weighted imaging (SWI) characteristics of hemoglobin degradation products resulting from old microhemorrhages. These alterations were associated with an area of hyposignal in T1 and hypersignal in T2, without diffusion restriction, characteristics of an old infarct area in the left parietal lobe (Figure 1).

One month after this MRI, the patient was submitted to a magnetic resonance angiography (MRA) of the head and neck. MRA was done with a 1.5 T magnetic resonance imager (Siemens, Erlangen, Germany) using a body coil. The images were acquired using the following parameters: coronal 3D gradient-echo fast low-angle shot (FLASH), TR/TE 3.5/1.37 msec; 25º flip angle; 136 x 512 matrix, 36.7 x 36.7 cm field of view; slab

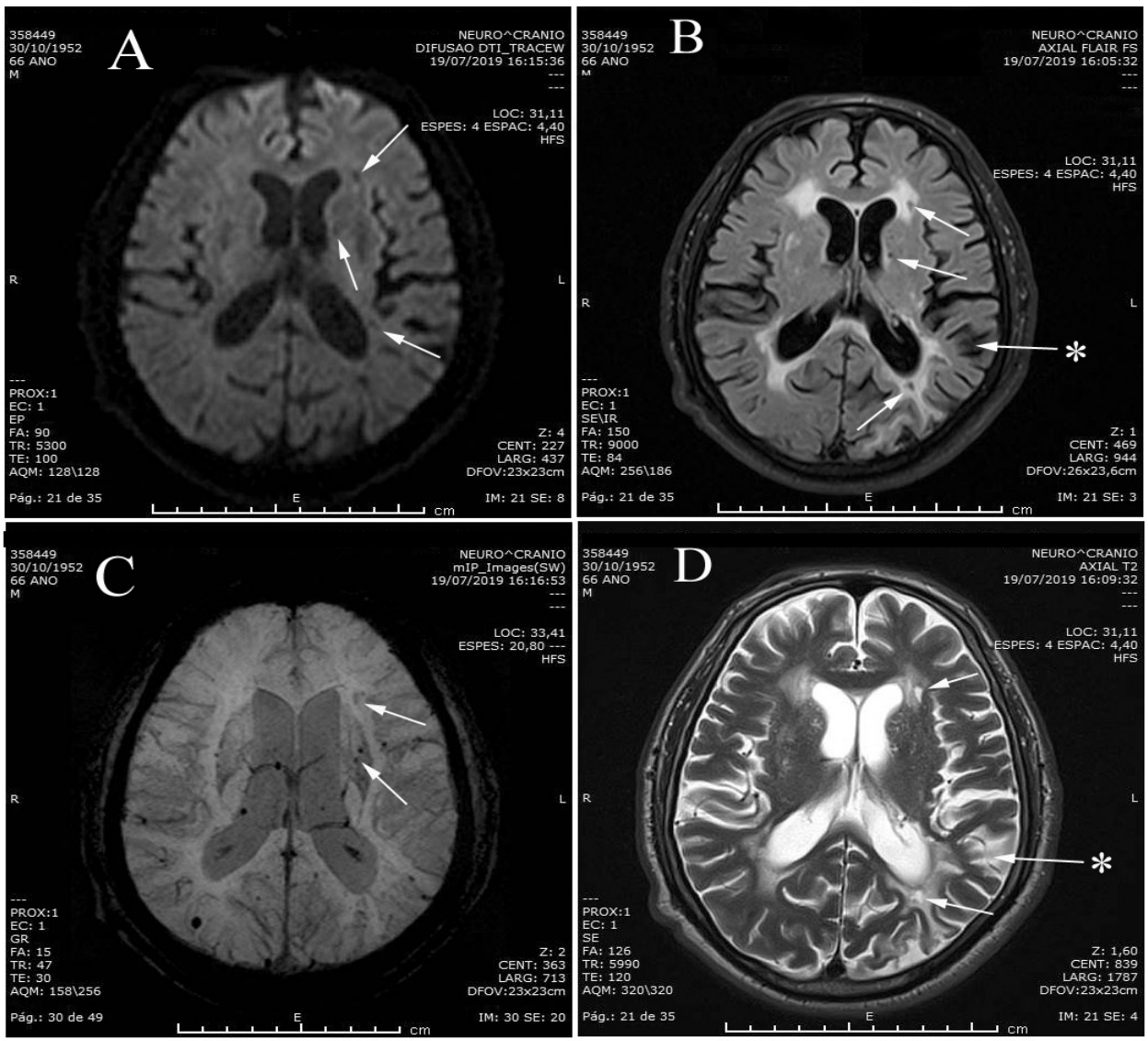

Figure 1. Magnetic resonance imaging exam (MRI) sample images. The images obtained evidenced global cerebral volume loss (A), lacunar infarcts (white arrows) at the internal capsule and basal nuclei regions and several punctiform low signal images in ponderal sequences from susceptibility-weighted imaging (SWI) (C). Note also an area of hyposignal (*) in T1 (B) and hypersignal (*) in T2 (D), without diffusion restriction, characteristics of an old infarct area in the left parietal lobe.

thickness 70 mm; partitions 88 and voxel size 1.33 x 0.64 x 1.15 mm; then 3D reconstructions of interest regions were done using the Synapse 3D Fujifilm software.

The brain MRA evidenced the same alterations described in the MRI, with no alterations of the cerebral blood vessels. The investigation of the blood vessels of the neck evidenced an anatomical variation of the aortic arch, the so-called bovine aortic arch (Figure 2), that might be related to the embolic cerebral infarcts. The bovine aortic arch shown by the MRA was formed by an aortic arch with two branches, being the first branch a common trunk that trifurcated into the following arteries: right subclavian, right common carotid and left common carotid (Figure 2). The second aortic arch branch was the left subclavian artery. No further anatomical variations were found in the exam.

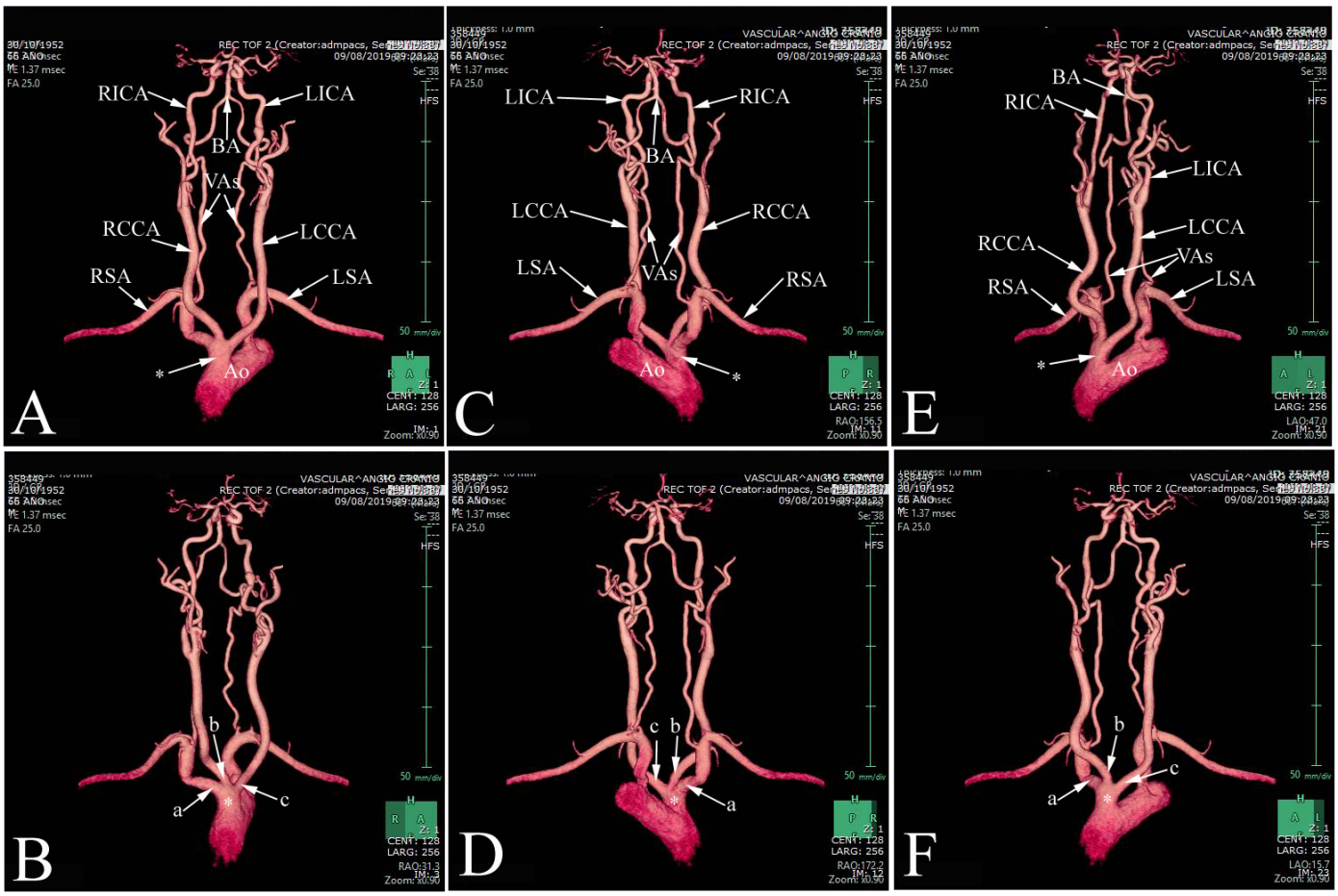

Figure 2. Magnetic resonance angiography exam (MRA) sample images. A and B represent an anterior view of the aortic arch (Ao), C and D represent a posterior view of the aortic arch (Ao) and E and F represent a right lateral view of the aortic arch (Ao). Main large vessels are indicated in figures A, C and D as follows: RSA = Right subclavian artery, LSA = Left subclavian artery, RCCA = Right common carotid artery, LCCA = Left common carotid artery, VAs = vertebral arteries, BA = basilar artery, RICA = Right internal carotid artery, LICA = Left internal carotid artery. The bovine aortic arch shown by the MRA was formed by an aortic arch (Ao) with two branches, being the first branch a common trunk (*) that trifurcated (Figures B, D and F) into the following arteries: right subclavian (a), right common carotid (b) and left common carotid (c). The second aortic arch branch was the left subclavian artery.

Discussion

We describe a relatively common variation of the aortic arch (bovine aortic arch) in a patient with important clinical symptoms, diagnosed by imaging investigation of the head and neck vasculature. Variations of the aortic arch pattern are directly related to developmental errors usually involving the persistence of structures that should disappear in normal conditions. Particularly for the aortic arch branches, variations are intimately associated with the development of the fourth arterial arches in the embryo.

The development of the definitive aortic arch and its branches takes place very early in fetal life, within the first few weeks after the initial embryo development, as described next.[9,10] At first, a common arterial trunk, the truncus arteriosus, arises from the primitive heart and divides into six paired arches to the head and neck.[9] Then, these arteries fuse on either side of the pharynx to form bilateral dorsal aortae. During the third week of intrauterine life, these dorsal aortae fuse caudally into a single descending aorta at the level of the fourth thoracic vertebra. The first, second, and fifth arches then regress while the third arches form the carotid arteries.[9] Then, asymmetric development occurs at the level of the fourth arch. The fourth arch on the right forms the brachiocephalic and right subclavian artery. On the left side, the fourth arch forms the left

subclavian artery, and the aortic arch itself, which subsequently joins the descending aorta beyond. Thus, the usual aortic arch in man, and of all mammals, is a left one produced by the persistence and development of the left fourth arch[10]. Persistence or obliteration of those various arches arising from the primitive heart, due to unexpected events in utero, may lead to anatomical variation.[9] In the case of a bovine aortic arch, there is an involvement of misleading events during the right carotid artery formation by the third primitive arch together with the brachiocephalic trunk formation by the fourth primitive arch on the right.

Despite having little or no physiological consequence in the vast majority of patients, aortic arch variations have significant implications for planning interventional vascular radiology and surgical procedures not only in the head and neck but also in the upper limbs.[9] Also, in recent years, thoracic aortic stenting and hybrid aortic reconstructive procedures are becoming more common and the recognition of these variations has assumed greater importance, to ensure safer and more accurate endovascular and surgical planning.[9]

The literature is giving more attention to the relation between aortic arch anatomical variations and diseases. It has been described that aortic arch variations are associated with increased risk of neurological events during carotid stent procedures,[5] either for symptomatic or asymptomatic patients with carotid stenosis. The relation between carotid stenosis and the presence of a bovine aortic arch was investigated by Baadh *et al.*[11] The authors found that despite the probable hemodynamic alterations associated with an altered flow pattern or turbulence that may occur in these patients,[11] no significant association between the presence of a bovine aortic arch and carotid stenosis was found. This is also true for the present case report in which, despite the neurological symptoms, carotid stenosis was not found. In spite of being a controversial issue,[12] some studies[13,14] have pointed to a direct relationship between the presence of a bovine aortic arch and the thoracic aorta disease, particularly at young ages. Again, this was not the case in our patient.

Despite being a relatively rare anatomical variation, the bovine aortic arch has been more and more frequently associated with different types of symptoms and disorders, particularly of neurological nature. Thus, we suggest that not only vascular surgeons but also neurologists keep the possibility of this variation in mind when investigating a symptomatic patient.

Conclusion

Embryological deviations of normal associated with this anatomical variation are discussed. Despite having little or no physiological consequence in the vast majority of patients, aortic arch variations have significant implications for planning interventional vascular radiology and surgical procedures not only in the head and neck but also in the upper limbs.

Acknowledgements

We thank Mr. Antônio Renato Meirelles e Silva, Experimental Neurology Laboratory for excellent technical support. Grant sponsor: FAPESP (Fundação de Amparo à Pesquisa do Estado de São Paulo); Grant sponsor: CNPq (Conselho Nacional de Pesquisa e Tecnologia); Grant sponsor: FAEPA (Fundação de Apoio ao Ensino, Pesquisa e Assistência do Hospital das Clínicas da Faculdade de Medicina de Ribeirão Preto da Universidade de São Paulo).

References

1. Lippert H, Pabst R. Arterial variations in man. Classification and frequency. J. F. Bergmann Verlag Muchen, 1985.
2. Layton KF, Kallmes DF, Cloft HJ, Lindell EP, Cox VS. Bovine aortic arch variant in humans: Clarification of a common misnomer. Am J Neuroradiol 2006;27:1541-42.
3. Spacek M, Veselka J. Bovine arch. Arch Med Sci 2012; 8: 166-167 doi: 10.5114/aoms.2012.27297
4. Arnáiz-García ME, González-Santos JM, López-Rodriguez J, Dalmau-Sorli MJ, Bueno-Codoñer M, Arévalo-Abascal A, Fdez García-Hierro JM, Arnáiz-García AM, Arnáiz J. A bovine aortic arch in humans. Indian Heart J. 2014;66:390-1. doi: 10.1016/j.ihj.2014.03.021.
5.cFaggioli GL, Ferri M, Freyrie A, Gargiulo M, Fratesi F, Rossi C, Manzoli L, Stella A. Aortic arch anomalies are associated with increased risk of neurological events in carotid stent procedures. Eur J Vasc Endovasc Surg. 2007;33:436e41.
6. Ahn SS, Chen SW, Miller TJ, Chen JF. What Is the True Incidence of Anomalous Bovine Left Common Carotid Artery Configuration? Ann Vasc Surg. 2014; 28: 381–385.
7. Sikka A, Jain A. Bilateral Variation in the Origin and Course of the Vertebral Artery. Anatomy Research International. 2012; Article ID 580765, 3 pages, 2012. https://doi.org/10.1155/2012/580765.
8. Bell DJ. Anatomical variants. Radiopaedia.org, rID: 57781, https://radiopaedia.org/articles/anatomical-variants?lang=us
9. Jakanani GC, Adair W. Frequency of variations in aortic arch anatomy depicted on multidetector CT. Clin Radiol. 2010;65:481-487. doi: 10.1016/j.crad.2010.02.003.
10. Bergman RA, Afifi AF, Miyauchi R, "Opus II: cardiovascular system vertebral artery variations," in Illustrated Encyclopedia of Human Anatomic Variation, R. A. Bergman, A. F. Afifi, and R. Miyauchi, Eds.,http://www.anatomyatlases.org/AnatomicVariants/Cardiovascular/Images0001/0095.shtml.
11. Baadh AS, Rockman CB, Mitnick RJ, Lim RP. Bovine arch and carotid artery atherosclerosis: are they related? Clin Imaging. 2014;38:681-685. doi: 10.1016/j.clinimag.2014.05.010
12. Angouras DC, Boudoulas KD, Boudoulas H. Bovine aortic arch: normal variant or a marker of aortopathy? Cardiology 2012;123:113–115. doi: 10.1159/000342790
13. Hornick M, Moomiaie R, Mojibian H, Ziganshin B, Almuwaqqat Z, Lee ES, Rizzo JA, Tranquilli M, Elefteriades JA: 'Bovine' aortic arch - a marker for thoracic aortic disease. Cardiology 2012;123:116-124.
14. Malone CD, Urbania TH, Crook SES, Hope MD: Bovine aortic arch: a novel association with thoracic aortic dilation. Clin Radiol. 2012; 67:28-31.

Mini Curriculum and Author's Contribution

1. Lincoln da Silva Freitas – MD; PhD. Contribution: Effective scientific and intellectual participation for the study; technical procedures; data acquisition, data interpretation; preparation and draft of the manuscript; critical review and final approval. ORCID: 0000-0003-0292-4541

2. Frederico Sassoli Fazan – BSc; MsC student. Contribution: effective scientific and intellectual participation for the study; technical procedures; data acquisition, data interpretation; preparation and draft of the manuscript; critical review and final approval. ORCID: 0000-0002-1941-0435

3. Fernando José Dias – DDS; PhD. Contribution: Design of the study, data interpretation, writing of case report and; critical review and final approval. ORCID: 0000-0001-9945-9185

4. Valéria Paula Sassoli Fazan – MD; PhD. Contribution: Guiding professor, responsible for technical procedures; preparation and draft of the manuscript; critical review and final approval. ORCID: 0000-0003-1293-5308

Received: March 1, 2020.
Publisehd October 20, 2020.
Publisehd on line October 30, 2020

Corresponding author
Valéria Paula Sassoli Fazan
Email: vpsfazan@yahoo.com.br